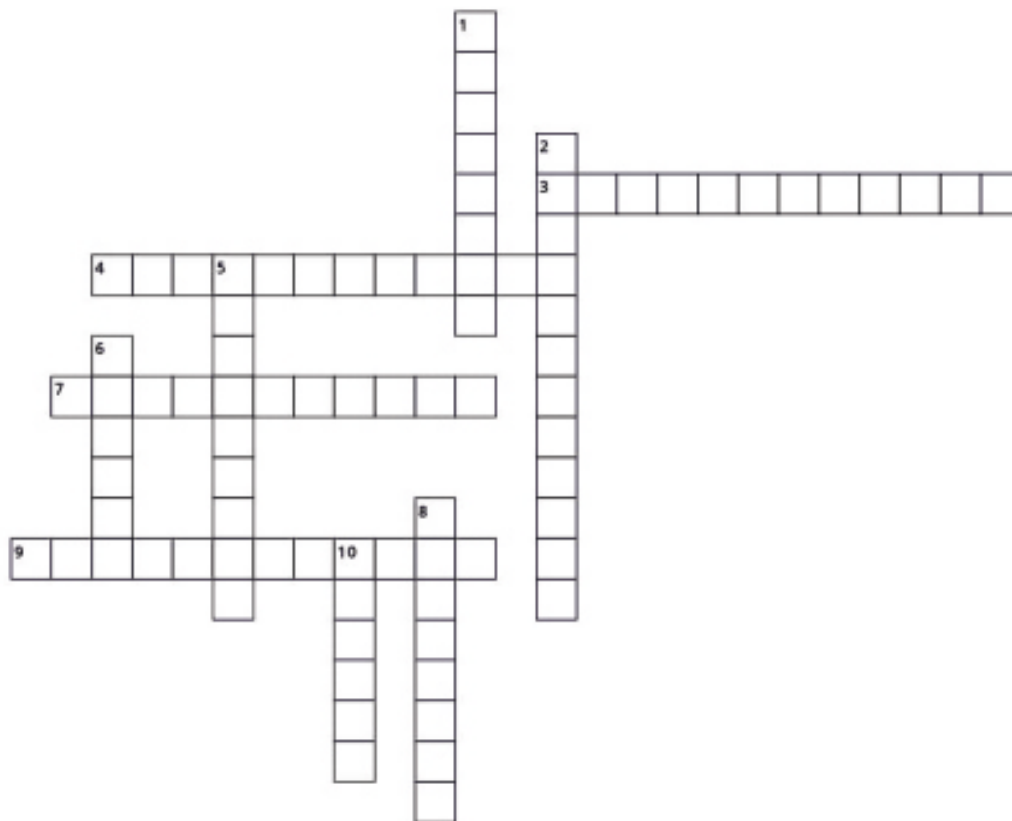


## Puzzle

**Dr. Anchal Tripathi**

Army Hospital, New Delhi



### Across

3. Most common secondary tumor in retinoblastoma patients.
4. this drug is used in newborns with suspected chlamydial conjunctivitis.
7. this drug helps blepharitis patients by changing lipid viscosity.
9. Smokers should avoid this

### Down

1. This phenomenon is considered to be an illusion.
2. MRI sign in patients with progressive Supranuclear palsy.
5. Paralysis of this nerve is the most common cause of vertical ocular misalignment.
6. a progressive study design.
8. Associated with PAX6 gene
10. In the collaborative normal glaucoma treatment study, progression was reduced by nearly three fold by reduction of IOP \_\_\_%.