

# Endophthalmitis in a Vitrectomised Eye - An Unexpected Visitor

Kshitij Raizada, MS, Mohit Gupta, MS  
Dipendra Shukla, MS, FPNK, Prabhat Ranjan, MS, FMRF  
Email for Correspondence : raizada.13@gmail.com,  
Prakash Netra Kendra, Lucknow



## Abstract

**Purpose:** This case report aims to highlight the rare incidence of endophthalmitis after pars plana vitrectomy and to elucidate the causative factors, implicated microorganisms, clinical features, prophylaxis, and treatment of this rare entity.

**Methods:** A 67-year-old male presented with complaints of a black spot in front of his right eye for 4 months. BCVA was CF@3m in RE and 6/9 in LE. On examination, RE had IMSC with a large macular hole, while LE was pseudophakic with an old macular tributary occlusion. The patient underwent Cataract surgery with 25G PPV + ILM Peeling + C3F8 in RE. 15 days later the patient developed endophthalmitis in the

operated eye. The patient underwent a vitreous lavage with intra-vitreous antibiotic injections. One week later, the patient developed Retinal Detachment in the same eye.

**Results:** The patient was operated for macular hole and later on treated for endophthalmitis and RD. His final visual acuity was CF@2m.

**Conclusion :** Endophthalmitis following Pars Plana Vitrectomy has limited reports in the literature and is relatively uncommon. This case report highlights the factors which could lead to such incidences and discusses how to treat and prevent its occurrence.

**Keywords :** Endophthalmitis, Pars Plana Vitrectomy, Macular Hole

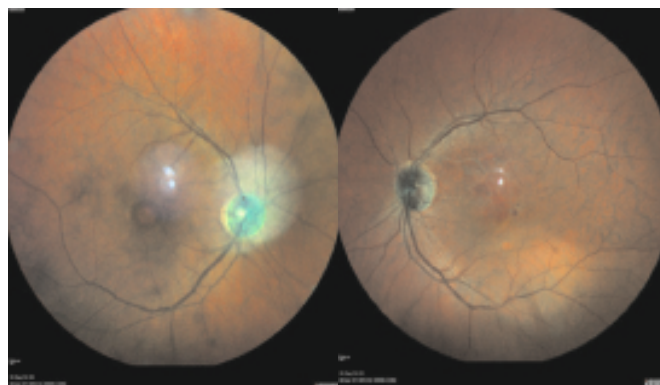
A 67-year-old male presented to our opd with complaints of a black spot in front of his right eye for the past 4 months.

Vision in the right eye was FC@3m and 6/9 in the left eye. With pinhole, vision in the left eye improved to 6/6 while there was no improvement in the right eye. The patient was a known hypertensive, controlled on medication.

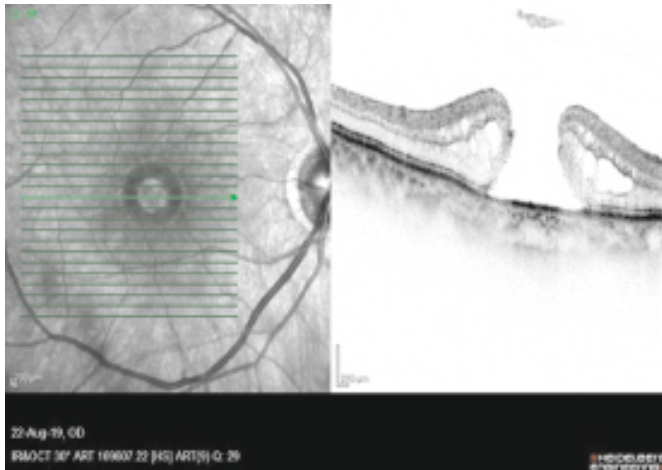
On examination, the right eye was found to have a posterior subcapsular and cortical cataract, while the left eye had a PCIOL in the bag.

Fundus examination revealed a large macular hole in the right eye and the left eye had an old macular tributary occlusion with non centre involving cystoid macular edema (Figure 1), (Figure 2) (Figure 3).

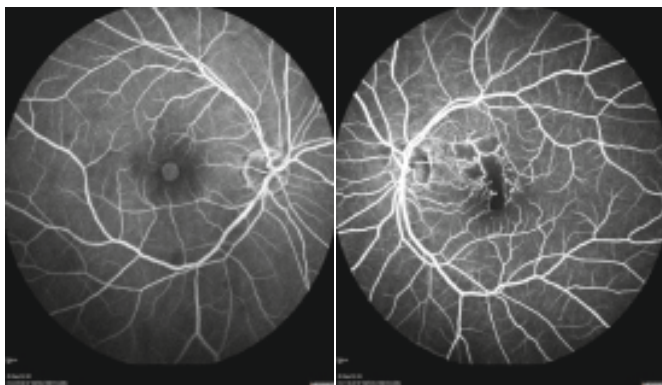
**Figure 1. Fundus picture showing full thickness macular hole in the right eye and supero-temporal sclerosed vessel, suggestive of old macular tributary occlusion, with macular edema in the left eye.**



**Figure 2. OCT of the right eye showing a large full thickness macular hole.**



**Figure 3. FFA of the right eye showing hyperfluorescence due to window defect owing to the macular hole and the left eye showing staining of the wall of the macular tributary vessel and capillary non perfusion area within the macula.**

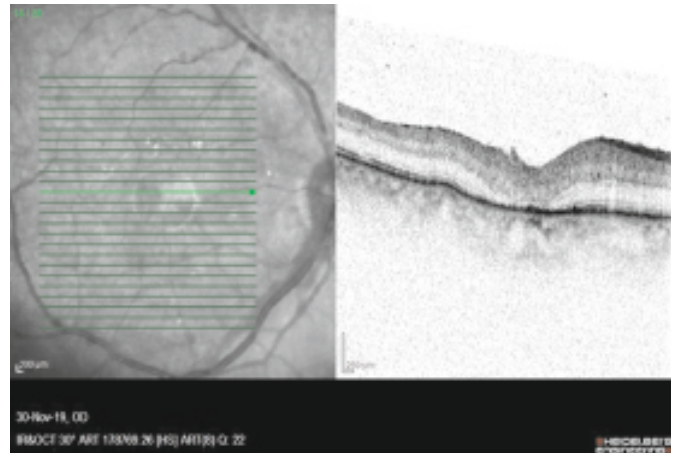


The patient underwent cataract surgery with monofocal IOL with 25G Vitrectomy + ILM Peeling + C3F8 Gas under local anaesthesia.

On post operative day 1, the right eye had mild corneal stromal keratopathy, PCIOL in the bag, and healthy looking retina with an 80% Gas Fill.

1 week later, the patient's vision in the right eye was FCCF. The gas bubble was at the level of superior vascular arcade (Figure 4).

**Figure 4. Right eye OCT one week after surgery.**



15 days after the surgery, the patient came with complaints of swelling, pain, and watering in the right eye for 1 day. The vision had dropped to HM in the right eye. The right eye had AC CELLS 1+ / Flare 1+ along with vitreous haze and severe exudation in the vitreous cavity. The patient was diagnosed with endophthalmitis. The patient underwent a Vitreous Lavage + intravitreal injection (Vancomycin (1mg in 0.1ml)+Ceftazidime(2.25mg in 0.1ml)+Dexamethasone (0.4mg in 0.1 ml)) under local anaesthesia. The patient was also started on Tab. Ciprofloxacin 750 mg BD, fortified Vancomycin and Ceftazidime eye drops, on hourly basis, and eye drop Prednisolone Acetate qid.

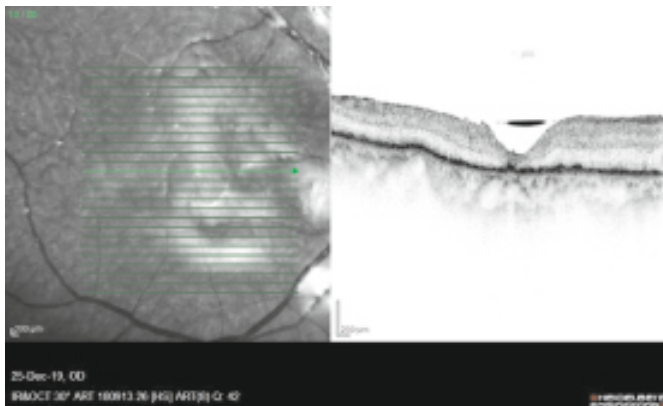
Culture reports suggested Coagulase Negative Staphylococcus Aureus. Anterior Chamber cells and flare and vitreous exudation didn't improve 2 days later and he was given a repeat dose of intravitreal (Vancomycin (1mg in 0.1ml)+Ceftazidime (2.25mg in 0.1ml) +Dexamethasone (0.4mg in 0.1 ml)).

3 days later, Anterior Chamber reaction and exudation had reduced and fundus glow had returned, with a hazy view of the disc. 5 days later, the vision had improved to 2/60. Fundus view was better and peripheral exudation in the vitreous cavity was noted (Figure 5.)

3 days later the patient came with diminution of vision in the same eye and he was noted to have a retinal detachment in the right eye. The patient underwent a

repeat vitrectomy + endolaser with silicon oil injection in the right eye.

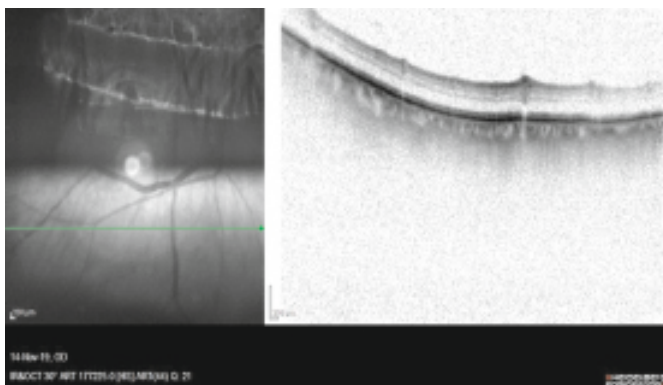
**Figure 5. RE OCT after 10 days of vitreous lavage.**



On Post-Op Day 7, his vision was CF@2m and retina was well attached. The patient was continued on topical steroid, antibiotic, and IOP lowering drugs.

The patient was examined 2 months later with a vision of CF@2m in the right eye, with retina well attached all around (Figure 6).

**Figure 6. RE OCT after RD surgery with silicon oil in situ.**



### **Discussion -**

Endophthalmitis in most of the cases is seen after cataract surgery or after intravitreal injections. The incidence of endophthalmitis, as reported in the literature, is 0.07%-0.4% after cataract surgery, and that after intravitreal injection, ranges from 0.04%-0.07%. Endophthalmitis is also common after trauma and after filtration surgeries for glaucoma.

Endophthalmitis after pars plana vitrectomy (PPV) is a rare entity as vitreous is like a nutrient-rich growth

medium for microorganisms, and sans the vitreous after PPV, chances of developing endophthalmitis are very bleak.

Being a rare entity, the reporting of such cases in the literature is quite scarce.<sup>1-5</sup>

The factors which are purportedly responsible for causing endophthalmitis post pars plana vitrectomy are as follows<sup>6,7</sup> :

#### **1. Post-surgery leaking wound**

Leaking sclerotomy sites after PPV may allow the microorganisms in the conjunctival cul-de-sac to gain access inside the vitreous cavity causing endophthalmitis. The incidence of endophthalmitis increases dramatically, if there is a tag of vitreous exuding from the site of sclerotomy, especially in a wound that has been left unsutured. Microorganisms use this vitreous strand as a scaffold to enter inside the vitreous cavity. This is known as the vitreous wick phenomenon.

#### **2. Intraocular tamponading agents**

Air, silicon oil, and expansile gases like C3F8, SF6 do not support the growth of microorganisms. They also seal the sites of sclerotomies well owing to the differential surface tension of these agents.<sup>8</sup> This provides good wound integrity.

The balanced salt solution, on the other hand, does not seal the site of sclerotomy as well as the above-mentioned agents, and therefore its use may facilitate the entry of microorganisms inside the vitreous cavity.

#### **3. Associated pharmacotherapy**

The use of subconjunctival antibiotics after PPV has shown to keep the incidence of endophthalmitis after PPV under check. Some centres do not follow this practice and it may be responsible for endophthalmitis after PPV.

Use of intravitreal anti-vegf injections, triamcinolone acetonide, dexamethasone implant concurrently with PPV may also be responsible for causing endophthalmitis following PPV.

#### **4. Surgeon's learning curve**

Increased operating time is considered to be one of the causative factors of endophthalmitis post PPV. Therefore, cases being operated by young surgeons might be at a slightly higher risk of developing

endophthalmitis after the surgery. Poorly constructed wounds might also be responsible for leaking wounds post operatively, thereby inviting infections.

### 5. Diabetes mellitus

Patients with uncontrolled diabetes mellitus and high blood sugar levels are naturally predisposed to develop infections in the post-operative phase. Diabetics are also likely to have a concurrent cataract, which would increase the operative time. There might also be the presence of complex tractional retinal detachment, which would again increase the operating time and would also require complex handling, both of which could lead to increased chances of developing endophthalmitis after the surgery.

#### **Microbiological spectrum**

A wide variety of microorganisms have been held responsible for causing endophthalmitis post vitrectomy. These include coagulase-negative staphylococci, ***Pseudomonas***, ***Propionibacterium***, enterococci, and ***Bacillus*** species.<sup>9</sup> Coagulase-negative staphylococci is the most common organism causing endophthalmitis after PPV.

#### **Clinical features**

Endophthalmitis following PPV, closely resembles endophthalmitis due to any other cause, in signs and symptoms.<sup>10</sup> Patients generally present with acutely painful, red-eye associated with/without watering and mucopurulent discharge. The presence of lid edema strongly raises the suspicion of endophthalmitis. These symptoms are accompanied with blurring/diminution of vision. Patients typically have hypopyon and dense vitritis, with exudation in the vitreous cavity. Although in some cases, the features may not be very marked, or there may be a delayed presentation, due to the absence of vitreous, which acts as a growth medium for microorganisms.

#### **Treatment**

Clinicians need to carry a high level of suspicion when a patient presents with symptoms of diminution of vision, pain, redness after surgery. It is always advisable to err towards the diagnosis of endophthalmitis when in doubt. Endophthalmitis should be treated as an ocular emergency.

Intravitreal antibiotic injections need to be

administered as soon as possible once the diagnosis is made. Antibiotics most commonly used are Vancomycin(1mg in 0.1ml) and Ceftazidime (2.25mg in 0.1ml). Other broad-spectrum antibiotics(Cefazolin, Amikacin, Moxifloxacin, Imipenem, Piperacillin/Tazobactam) may also be used. Intravitreal Dexamethasone(0.4mg in 0.1ml) is also given concurrently to counter the inflammation inside the eye.

If based on clinical examination, fungal etiology is suspected, then intravitreal Voriconazole950-100ug in 0.1ml/Amphotericin-B(5ug in 0.1ml) is injected and the steroid is contraindicated.

Before injecting, a sample from the vitreous cavity should be taken and sent for culture and sensitivity. If media is clear and visibility is good, vitrectomy may be done to clear the bacterial/fungal load as much as possible.

If there is gas/silicon oil in the vitreous cavity, then the sample may be taken from the anterior chamber. Fortified topical antibiotics and oral antibiotics are included in the post-injection regime. Topical steroids may be included if fungal etiology has been ruled out and the cornea is healthy.

The patient needs to be called for frequent follow-up visits (preferably every 3 days) and intravitreal injections need to be repeated as per the need. Antibiotics may be altered as per culture and sensitivity reports.

#### **Prevention**

Preoperative asepsis is a must. 10% povidone-iodine should be used to clean the lids and lashes prior to every surgery.<sup>11</sup> A few drops of 5% povidone-iodine solution should be instilled in the conjunctival cul-de-sac and left for a few minutes. This povidone-iodine should be thoroughly washed and then the surgery should be commenced.

This practice is known to reduce ocular flora considerably and has shown to drastically reduce the chances of developing endophthalmitis after surgery. Lid speculum and adhesive surgical drape should be used to keep the eyelashes away from the field of surgery.

Patients who have any signs of ocular/periorcular

infection (such as stye, blepharitis, dacryocystitis, etc) should be treated for the infective etiology first and the elective surgery should be taken up only after the infection has completely subsided.

Some surgeons prefer to mix antibiotics in the saline infusion fluid. Although this practice is controversial and not universally followed.

While making sclerotomy, it is advised to displace the conjunctiva with a swab before making an entry with the trocar. This ensures that the conjunctival and scleral entry wounds are not in the same line, which thereby decreases the chances of microorganisms gaining an entry inside the vitreous cavity.

The entry of the trocar should be in a beveled manner and not perpendicular to the sclera. This makes the wound self-sealing and reduces the chances of a leaking wound post-surgery.

After the surgery, the proper closure of the wounds needs to be ensured and the wounds may be sutured if at all there is a doubt of leaking sclerotomy.

### **Visual outcomes**

Visual gain after the treatment of endophthalmitis post-PPV is quite varied. In most of the cases, the gain of vision post-PPV endophthalmitis is quite poor which may also be attributed to the primary retinal pathology.<sup>12,13</sup> As per several study reports, the visual outcomes after post-PPV endophthalmitis are poor as compared to endophthalmitis after cataract surgery.

### **Conclusion**

Endophthalmitis after PPV is a rare entity but it may have grave consequences. It usually carries a very poor prognosis despite aggressive treatment and best efforts from the treating physician. Prevention is the best cure for this entity and every measure needs to be taken to ensure that chances of infection post PPV are minimal.

### **References**

1. Mollan SP, Mollan AJ, Konstantinos C, Durrani OM, Butler L. Incidence of endophthalmitis following vitreoretinal surgery. *Int Ophthalmol.* 2009;29:203–205.
2. Chen JK, Khurana RN, Nguyen QD, Do DV. The incidence of endophthalmitis following transconjunctival sutureless 25 vs 20 gauge vitrectomy. *Eye.* 2009;23:780–784.
3. Scott IU, Flynn HW, Jr, Dev S, et al. Endophthalmitis after 25 gauge and 20 gauge pars plana vitrectomy: incidence and outcomes. *Retina.* 2008;28:138–142.
4. Kunimoto DY, Kaiser RS, Wills Retina Service. Incidence of endophthalmitis after 20 and 25 gauge vitrectomy. *Ophthalmology.* 2007;114:2133–2137.
5. Eifrig CW, Scott IU, Flynn HW, Jr, Smiddy WE, Newton J. Endophthalmitis after pars plana vitrectomy: incidence, causative organisms, and visual acuity outcomes. *Am J Ophthalmol.* 2004;138:799–802.
6. Park JC, Ramasamy B, Shaw S, Prasad S, Ling RH. A prospective and nationwide study investigating endophthalmitis following pars plana vitrectomy: incidence and risk factors. *Br J Ophthalmol.* 2014;94:529–533.
7. Shimada H, Nakashizuka H, Hattori T, Mori R, Mizutani Y, Yuzawa M. Incidence of endophthalmitis after 20 and 25 gauge vitrectomy: causes and prevention. *Ophthalmology.* 2008;115:2215–2220.
8. Chiang A, Kaiser R, Avery R, et al. Endophthalmitis in microincision vitrectomy. Outcomes of gas-filled eyes. *Retina.* 2011;31:1513–1517.
9. Abi-Ayad N, Gambrelle J, Duquesne N, Fleury J, Grange JD, Kodjikian L. Endophthalmitis after plana vitrectomy: incidence, microbiology and visual outcomes. *J Fr Ophthalmol.* 2007;30:397–402.
10. Zhang S, Ding X, Hu J, Gao R. Clinical features of endophthalmitis after vitreoretinal surgery. *Yan Ke Xue Bao.* 2003;19:39–43.
11. Kaiser RS, Prenner J, Scott IU, et al. The Microsurgical Safety Task Force: evolving guidelines for minimizing the risk of endophthalmitis associated with microincisional vitrectomy surgery. *Retina.* 2010;30:692–699.
12. Oshima Y, Kadonosono K, Yamaji H, et al. Multicenter survey with a systematic overview of acute-onset endophthalmitis after transconjunctival microincision vitrectomy surgery. Japan Microincision Vitrectomy Surgery Study Group. *Am J Ophthalmol.* 2010;150:716–725.e1.
13. Wani VB, Al Sabti K, Kumar N, et al. Endophthalmitis after vitrectomy and vitrectomy combined with phacoemulsification: incidence and visual outcomes. *Eur J Ophthalmol.* 2009;19:1044–1049.