

# Descemetopexy- A Little More Than Just Providing Support!! A Gist on Descemet Membrane Detachment and Descemetopexy Procedure

Kanika Bhardwaj\*, Tulika Chauhan, Sagarika Patyal

Centre for Sight Hospital, New Delhi, Delhi, India

## Abstract

Descemet membrane detachment can be seen after any intraocular procedure but is more common after cataracts and corneal surgeries, especially in the hands of novice surgeons early in their training period. Prompt recognition and appropriate management can prevent the decompensation of cornea timely. Descemetopexy is a popular method to reduce corneal edema and improve patient prognosis. This article gives an insight into the procedure as well as the identification and management of a descemet membrane detachment.

**Keywords:** Descemetopexy, Descemet membrane detachment, Detachment, C3F8, SF6.

## INTRODUCTION

Descemet membrane detachment (DMD) is a serious complication of intraocular surgeries. It has been reported to occur in as much as 43% of cases after cataract surgery.<sup>1</sup> It refers to the separation of Descemet's membrane (DM) from the stroma, which can lead to visual impairment and other complications. This review article will discuss the etiology, classification, and management strategies for DMD intraoperatively and postoperatively.

### Etiology

The exact cause of DMD is not fully understood. However, detachment is believed to occur due to mechanical stress during surgery, such as excessive pressure, manipulation, or trauma. It can also occur due to a weakened or abnormal DM, such as in patients with Fuchs' corneal endothelial dystrophy or other corneal diseases.<sup>2</sup>

There are several causes of DMD, including:

- **Trauma:** Direct trauma to the eye can cause DMD. This may occur from a blunt or penetrating injury to the eye.
- **Intraocular pressure changes:** Changes in intraocular pressure, such as during glaucoma surgery or after a trabeculectomy, can cause DMD. This is due to the mechanical stress on the cornea, which can lead to the detachment of the DM.
- **Corneal endothelial diseases:** Corneal endothelial diseases such as Fuchs endothelial corneal dystrophy can lead to

DMD. This is because the corneal endothelium plays a crucial role in maintaining the attachment of the DM to the cornea.

- **Corneal surgery:** DMD can occur as a complication of corneal surgeries such as deep anterior lamellar keratoplasty (DALK), penetrating keratoplasty (PKP), or Descemet's membrane endothelial keratoplasty (DMEK). These surgeries can cause mechanical stress on the cornea, leading to DMD.
- **Inflammation:** Inflammatory conditions such as uveitis or iritis can cause DMD due to inflammation and swelling in the eye.
- **Congenital abnormalities:** Rarely, congenital abnormalities of the cornea or anterior segment of the eye can lead to DMD.

DMDs are rare with experienced surgeons but are frequently seen in surgical cases of young and novice surgeons operating during the early times of their residency.<sup>3</sup> The reason for such an occurrence could be the more anterior manipulation

Address for correspondence: Kanika Bhardwaj,  
Centre for Sight Hospital, New Delhi, Delhi, India  
E-mail: drkanikabhardwaj1@gmail.com

©Authors, 2023. Open Access. This article is licensed under a Creative Commons Attribution 4.0 International License, which permits use, sharing, adaptation, distribution and reproduction in any medium or format, as long as you give appropriate credit to the original author(s) and the source, provide a link to the Creative Commons licence, and indicate if changes were made. The images or other third party material in this article are included in the article's Creative Commons licence, unless indicated otherwise in credit line to the material. If material is not included in the article's Creative Commons licence and your intended use is not permitted by statutory regulation or exceeds the permitted use, you will need to obtain permission directly from the copyright holder. To view a copy of this licence, visit <https://creativecommons.org/licenses/by-nc-sa/4.0/>.



UP JOURNAL OF OPHTHALMOLOGY

An Official Journal of Uttar Pradesh State Ophthalmological Society,  
UPSOS (Northern Ophthalmological Society, NOS)

p-ISSN: 2319-2062

DOI: 10.56692/upjo.2023110201

**How to cite this article:** Bhardwaj K, Chauhan T, Patyal S. Descemetopexy: A Little More Than Just Providing Support!! A Gist on Descemet Membrane Detachment and Descemetopexy Procedure. UP Journal of Ophthalmology. 2023;11(2): 36-39.

**Received:** 19-07-23, **Accepted:** 13-08-23, **Published:** 20-09-23

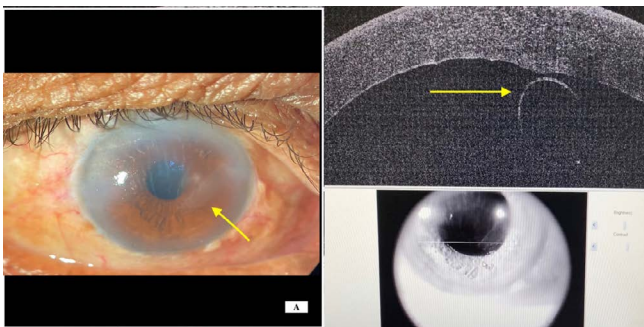
during phacoemulsification surgery and difficulty in corneal incision maneuvering by young surgeons. In our institute itself during resident training, Descemet detachment complication occurs at a frequency of 2 cases per month (on average 12-20 Descemetopathy procedures are done in a year).

### Identification

Early detection of DMD is essential for prompt management and better outcomes.

The following are some common ways to detect DMD

- **Slit-lamp examination:** A cloudy cornea on a post-operative visit, with corneal edema, should always be suspected for DMD. A slit-lamp examination is the most common method used to detect DMD. Clinical examination on slit lamp can throw light upon the corneal layers and their status post-surgery. The slit beam should be focused directly on the cornea using a thin slit and the highest magnification. Even a retro illumination exam can delineate the extent of DMD and reveal folds in a torn flap when present. An edematous cornea appears hazy and thickened. The pachymetry readings can even reveal corneal thickness in the 700 to 800  $\mu$  range. While SLE can give an idea, however in cases of dense corneal keratopathy and edema, modalities such as Anterior segment optical coherence tomography (AS-OCT) and Scheimpflug imaging are useful tools in cases with dense corneal edema and can better conclude the occurrence of DMD.<sup>4</sup>
- **Anterior segment optical coherence tomography (AS-OCT):** AS-OCT is a non-invasive imaging technique that provides high-resolution images of the cornea.<sup>5</sup> It can help to visualize the extent of the detachment and identify any associated abnormalities. Figure 1A shows a clinical picture and 1B shows ASOCT in the right eye of a patient one week after cataract surgery.
- **Specular microscopy:** Specular microscopy is a technique that uses a specialized microscope to examine the corneal endothelium. This can help assess the corneal endothelium's integrity and identify any changes that may indicate DMD. Specular microscopy helps predict the chances of DMD pre-operatively by diagnosing diseased



**Figure 1:** Descemet Membrane Detachment. 1A) clinical picture of the right eye showing torn and folded DM as depicted by the arrow. 1B) shows ASOCT in the area of detachment. Courtesy: Centre for Sight Eye Institute, Dwarka, New Delhi.

endothelium such as in FECD (Fuchs' Endothelial Corneal Dystrophy), but it is of not much use in post-operative edematous corneas.

- **Ultrasound biomicroscopy (UBM):** UBM is an imaging technique that uses high-frequency sound waves to visualize the anterior segment of the eye. It can help to detect DMD and assess the extent of the detachment. While ASOCT only scans a particular length of the cornea, UBM can give a complete picture at once.<sup>6</sup>
- **Corneal topography:** Corneal topography is a diagnostic tool that provides a detailed map of the cornea's shape and curvature. It can help to detect any irregularities in the corneal surface that may be associated with DMD, usually not required mostly.

A keen observation in the early post-operative period with a high index of suspicion in cases of prolonged or complicated surgeries can help detect DMD early and provide prompt management. DMD can cause blurred vision, discomfort, and other symptoms and such patients should not be sent away without proper evaluation.

### Classification

There are multiple classification systems available,<sup>3,7,8</sup> but a simplified clinical system can be utilized to decide on intervention as follows.

DMD can be classified into three categories based on the severity of detachment:

- **Partial detachment:** In this type, the detachment involves less than 50% of the DM. It can be managed conservatively with medical treatment. Refer to Figure 2.
- **Complete detachment:** In this type, the detachment involves more than 50% of the DM. It requires surgical intervention for management (as depicted in Figure 1).
- **Total detachment:** In this type, the DM is completely detached from the cornea. It is a rare complication and requires urgent surgical intervention.

### Management Strategies

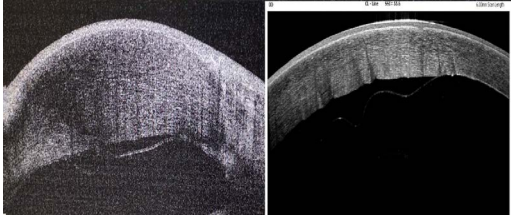
The management of Descemet's membrane detachment (DMD) depends on the detachment's severity and the timing of the detection. Prompt diagnosis and management are essential for the best possible visual outcomes.

### Intraoperative Management

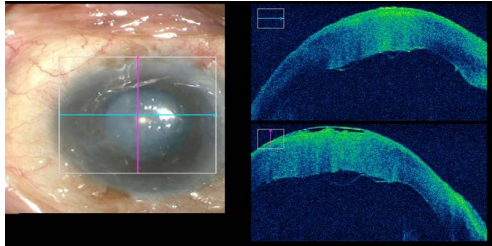
#### Partial Detachment

Descemetopathy is a surgical procedure that is performed to treat descemet's membrane detachment (DMD) in the eye. This procedure involves reattaching the detached descemet's membrane (DM) to the cornea.

If a partial DMD is detected during surgery, the surgeon may attempt to reposition the membrane using an air bubble or other techniques. (Refer to Figure 3). The air bubble technique involves injecting a small amount of air into the anterior chamber, which lifts the DM and allows it to reposition against the stroma. The surgeon may also try to manipulate the DM using forceps or other surgical instruments to reattach it. The



**Figure 2:** partial DMD involving <50%



**Figure 3:** Intraoperative ASOCT assisted during Descemetopexy showing the exact location and size of DMD. Courtesy: Centre for Sight Eye Institute, Dwarka, New Delhi.

air can give good surgical outcomes<sup>9</sup> however, it is absorbed quickly from the eye in about 24-36 hours and hence not suitable for prolonged tamponade.

The most commonly used gases for descemetopexy are sulfur hexafluoride (SF<sub>6</sub>) and perfluoro propane (C<sub>3</sub>F<sub>8</sub>) at their expansile concentrations.<sup>10,11</sup> These gases are used because they are inert, non-flammable, and have a low solubility in aqueous solutions, which allows them to remain in the anterior chamber for a longer duration. At our institute, we use both 20% SF<sub>6</sub> as well as 14% C<sub>3</sub>F<sub>8</sub> depending upon the availability. C<sub>3</sub>F<sub>8</sub> is used in more severe cases or large DMDs requiring prolonged tamponade.

The Descemetopexy procedure typically involves the following steps:

1. **Anesthesia:** The patient is typically given local anesthesia, which involves injecting a numbing agent around the eye.
2. **Creation of an air bubble:** A small amount of air is injected into the eye's anterior chamber to lift the detached DM and bring it closer to the cornea.
3. **Injection of gas:** The gas (SF<sub>6</sub> or C<sub>3</sub>F<sub>8</sub>) is then injected into the anterior chamber to replace the air bubble. The gas bubble will exert pressure on the DM and cornea, allowing them to adhere to each other.
4. **Head positioning:** The patient may be asked to tilt their head in a certain position to allow the gas bubble to properly adhere to the DM and cornea.
5. **Monitoring:** The patient will be closely monitored postoperatively to ensure that the gas bubble remains in place and the DM has reattached to the cornea.

**Complications of Descemetopexy may include<sup>12</sup>**

1. **Increased intraocular pressure:** The gas bubble may cause an increase in intraocular pressure, which can be managed with medications (mydriatics and anti-glaucoma medicines) or by releasing the bubble to decompress the chamber.

2. **Corneal endothelial cell loss:** The gas bubble can cause mechanical trauma to the corneal endothelium, which may lead to endothelial cell loss.
3. **Cataract formation:** Long-standing gas bubbles can cause cataract formation, which may require surgical intervention.
4. **Recurrence of DMD:** Despite successful reattachment of the DM, there is still a risk of recurrence of DMD.

### Complete or Total Detachment

If a complete or total DMD is detected during surgery, the surgeon may need to perform a DM reattachment surgery. There are different techniques for DM reattachment, including the “pull-through” technique, the “injection” technique, and the “suturing” technique.<sup>2</sup>

The pull-through technique involves passing a suture through the DM and then pulling it through the cornea to reposition the DM. The injection technique involves injecting a small amount of air or gas into the anterior chamber to reposition the DM. The suturing technique involves suturing the DM back into place using fine sutures.

In cases of loss of descemet membrane or total DMD, additional surgical interventions may be required, such as a corneal transplant or posterior lamellar keratoplasty in the form of descemet stripping endothelial keratoplasty (DSEK)/ Descemet stripping automated endothelial keratoplasty (DSAEK) or Descemet's membrane endothelial keratoplasty (DMEK). A corneal transplant involves replacing the damaged or detached DM with a healthy donor cornea. DSAEK involves the implantation of a thin donor graft consisting of an endothelium-descemet membrane complex with some posterior stroma. On the other hand, DMEK involves transplanting only a thin layer of the DM and endothelium from a donor cornea into the patient's eye. DMEK scrolls being thinner than the negative lenticular effect of DSAEK grafts, are theoretically less prone to refractive surprises due to the absence of a donor lamellar interface as seen with DSEK/DSAEK and have the added advantage of faster recovery time.<sup>13</sup>

### Post-operative Management

After surgery, the patient may be prescribed topical medications, such as steroids and antibiotic eye drops, to prevent inflammation and infection. They may also be advised to avoid activities that increase intraocular pressure, such as heavy lifting or straining. Correct head positioning is advised to ensure adequate attachment. They will also need close follow-ups with their ophthalmologist to monitor for any signs of complications, such as corneal edema, graft rejection, or infection.

### CONCLUSION

Descemet's membrane detachment is a rare but serious complication of intraocular surgeries at the hands of experienced surgeons. However, when it comes to young

surgeons on the precipice of beginning their surgical training, DMDs are frequent. It can lead to visual impairment and other complications in the patients as well as lower the surgeon's confidence. The management of DMD depends on the severity of the detachment and can include conservative medical treatment or surgical intervention. Descemetopathy is a procedure that can effectively reattach a detached Descemet's membrane to the cornea. The use of SF6 or C3F8 gas allows for prolonged tamponade of the DM, which allows for proper adhesion to the cornea. Nonetheless, this procedure may come with certain risks and complications, which should be discussed with the patient before the procedure. Post-operative management includes monitoring for any signs of complications and prescribing appropriate medications. With prompt and appropriate management, the prognosis for patients with DMD can be good.

## REFERENCES

1. Monroe WM. Gonioscopy after cataract extraction. *South Med J*. 1971;64:1122–4.
2. Singhal D, Sahay P, Goel S, Asif MI, Maharana PK, Sharma N. Descemet membrane detachment. *Surv Ophthalmol* [Internet]. 2020 [cited 2023 Mar 8];65:279–93. Available from: <https://www.sciencedirect.com/science/article/pii/S0039625720300023>
3. Kumar DA, Agarwal A. Managing Descemet Membrane Detachment by HELP Algorithm. *Off Sci J Delhi Ophthalmol Soc* [Internet]. 2016 [cited 2023 Mar 8];27:128–31. Available from: <https://www.djo.org.in/articles/27/2/managing-descemet.html>
4. Bhatia HK, Gupta R. Delayed-onset descemet membrane detachment after uneventful cataract surgery treated by corneal venting incision with air tamponade: a case report. *BMC Ophthalmol*. 2016;16:35.
5. Guo P, Pan Y, Zhang Y, Tighe S, Zhu Y, Li M, et al. Study on the classification of Descemet membrane detachment after cataract surgery with AS-OCT. *Int J Med Sci* [Internet]. 2018 [cited 2023 Mar 8];15:1092–7. Available from: <https://www.ncbi.nlm.nih.gov/pmc/articles/PMC6097261/>
6. Osman EA. The benefit of ultrasound biomicroscopy (UBM) in management of total Descemet's membrane detachment after deep sclerectomy surgery. *Int Ophthalmol* [Internet]. 2011 [cited 2023 Mar 8];31:345–8. Available from: <https://doi.org/10.1007/s10792-011-9462-8>
7. Mackool RJ, Holtz SJ. Descemet Membrane Detachment. *Arch Ophthalmol* [Internet]. 1977 [cited 2023 Mar 8];95:459–63. Available from: <https://doi.org/10.1001/archophth.1977.04450030101014>
8. Jacob S, Agarwal A, Chaudhry P, Narasimhan S, Chaudhry VN. A new clinico-tomographic classification and management algorithm for Descemet's membrane detachment. *Contact Lens Anterior Eye* [Internet]. 2015 [cited 2023 Mar 8];38:327–33. Available from: <https://www.sciencedirect.com/science/article/pii/S136704841500051X>
9. Chaurasia S, Ramappa M, Garg P. Outcomes of air descemetopathy for Descemet membrane detachment after cataract surgery. *J Cataract Refract Surg* [Internet]. 2012 [cited 2023 Mar 8];38:1134–9. Available from: <https://www.sciencedirect.com/science/article/pii/S0886335012004713>
10. Garg J, Mathur U, Acharya MC, Chauhan L. Outcomes of Descemetopathy with Isoexpansile Perfluoropropane after Cataract Surgery. *J Ophthalmic Vis Res* [Internet]. 2016 [cited 2023 Mar 8];11:168–73. Available from: <https://www.ncbi.nlm.nih.gov/pmc/articles/PMC4926564/>
11. Huang H-C, Jan R-L, Tseng S-H, Lee C-Y, Wei F-T, Chang Y-S. Management of Descemet's Membrane Detachment after Cataract Surgery—A Case Series. *Y Rep* [Internet]. 2020 [cited 2023 Mar 8];3:13. Available from: <https://www.mdpi.com/2571-841X/3/2/13>
12. Odayappan A, Shivananda N, Ramakrishnan S, Krishnan T, Nachiappan S, Krishnamurthy S. A retrospective study on the incidence of post-cataract surgery Descemet's membrane detachment and outcome of air descemetopathy. *Br J Ophthalmol*. 2018;102:182–6.
13. Ham L, Dapena I, Moutsouris K, Balachandran C, Frank LE, van Dijk K, et al. Refractive change and stability after Descemet membrane endothelial keratoplasty. Effect of corneal dehydration-induced hyperopic shift on intraocular lens power calculation. *J Cataract Refract Surg*. 2011;37:1455–64.