

A Case Report of a Child Suffering from Combined Hamartoma of Retina and Retinal Pigment Epithelium

Perwez Khan¹, Shalini Mohan¹, Tejasvini Chandra^{2*}

¹Department of Ophthalmology, GSVM Medical College, Kanpur, Uttar Pradesh, India

²Vitreo-retina Services, Eye -Q Super specialty Eye Hospitals, Gurugram, Haryana, India

Abstract

A 2^{1/2} years old male baby presented to us with complain of not following light both eyes. Anterior segment of both eyes were normal. Fundus examination revealed CHRRPE lesions in both eyes. Diagnosis of Combined hamartoma of the retina and retinal pigment epithelium mainly depends on fundus manifestations, FFA and OCT. B ultrasound scan is useful for differential diagnosis. Surgical dissection can be effective in the treatment of vitreomacular traction associated with CHRRPE with a good functional and anatomical outcome.

Keywords: CHRRPE, Hamartoma, Retina

INTRODUCTION

Combined hamartoma of the retina and retinal pigment epithelium (CHRRPE) is an uncommon and benign ocular tumor. Typically single and unilateral, which may compromise the optic disc, macula and less frequently the periphery. This congenital lesion consists of glial cells, vascular tissue, and sheets of pigment epithelial cells.¹ It is commonly found in healthy young children; however, some cases associated with systemic diseases have been described. We report a case of a CHRRPE.

Clinical Case

A 2½ yrs old male baby who has been followed from December 2017 to till date. There was a history of late preterm, i.e., 7½ months twin delivery, out of which 1st twin died. The patient's birth weight was 1.8 kg and was admitted to NICU for 1½ month. The parents brought the baby for ROP screening when this lesion was found out. Fundus examination of the right eye showed a yellow-grey mass, slightly elevated above the optic disc and peripapillary retina, extending to the macula and hyper-pigmented areas around the lesion, also tortuous vessels (Figure 1).

On USG B-scan- there was mild thickening of retina of right eye (Figure 2).

OCT-demonstrated an elevated lesion with loss of normal architecture of optic nerve and gradual transition from this

lesion to normal retinal layers, the retinal pigment epithelium is intact. Macula demonstrates loss of foveal depression and presence of hyper-reflecting nodules (Figure 3).

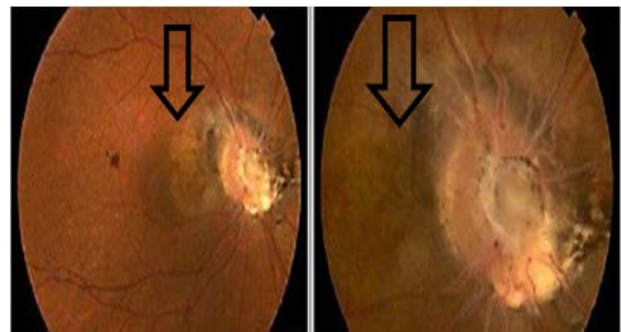


Figure 1: BE fundus photo showing elevated mass above optic disc extending to macula -CHRRPE lesion (black arrows).

Address for correspondence: Tejasvini Chandra,

Vitreo-retina Services, Eye -Q Super specialty Eye Hospitals, Gurugram, India

E-mail: tejasvini_chandra@yahoo.co.in

© UPIO, 2023 Open Access This article is licensed under a Creative Commons Attribution 4.0 International License, which permits use, sharing, adaptation, distribution and reproduction in any medium or format, as long as you give appropriate credit to the original author(s) and the source, provide a link to the Creative Commons licence, and indicate if changes were made. The images or other third party material in this article are included in the article's Creative Commons licence, unless indicated otherwise in a credit line to the material. If material is not included in the article's Creative Commons licence and your intended use is not permitted by statutory regulation or exceeds the permitted use, you will need to obtain permission directly from the copyright holder. To view a copy of this licence, visit <https://creativecommons.org/licenses/by-nc-sa/4.0/>.

How to cite this article: Khan P, Mohan S, Chandra T. A Case Report of a Child Suffering from Combined Hamartoma of Retina and Retinal Pigment Epithelium. UP Journal of Ophthalmology. 2023;11(1): 28-29.
Received: 14-12-2022, **Accepted:** 06-01-2023, **Published:** 31-03-2023



UP JOURNAL OF OPHTHALMOLOGY

An Official Journal of Uttar Pradesh State Ophthalmological Society,
UPSOS (Northern Ophthalmological Society, NOS)

p-ISSN: 2319-2062

DOI: 10.56692/upjo.2023110107

Treatment

The patient underwent right eye PPV with ILM peeling with traction release under GA. PPV with membrane peeling for ERM associated with CHRRPE can result in improved retinal architecture and visual acuity. Now the baby is able to follow the light.²

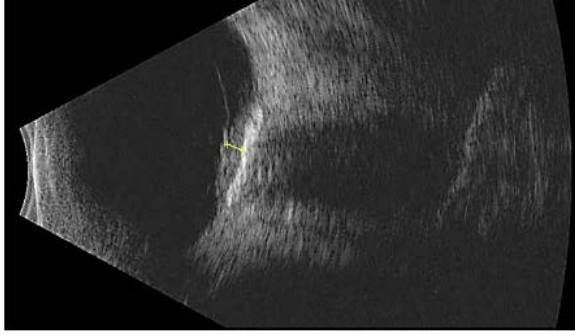


Figure 2: USG B-scan showing thickening of retina

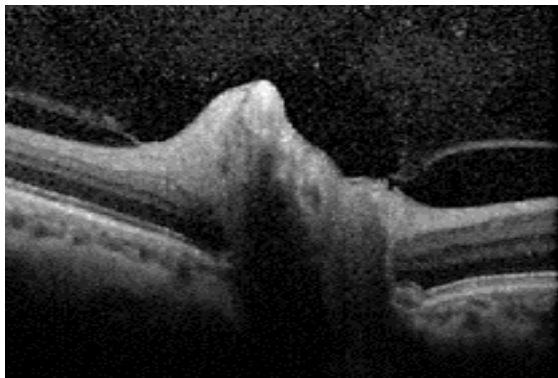


Figure 3: OCT showing loss of architecture of optic nerve

CONCLUSION

Combined hamartoma of the retina and retinal pigment epithelium (RPE) is a rare, congenital, and benign tumor that may be mistaken with a choroid melanoma or retinoblastoma. These tumors often show an epiretinal membrane, tangential traction, disorganization of the retinal layers, and underlying uniform choroidal thinning.³ Diagnosis of CHRRPE mainly depends on fundus manifestations, FFA and OCT. USG B-scan is useful for differential diagnosis.⁴ Surgery aims to reduce the vitreous traction and establish surface regularity. Timely surgical interventions may yield gratifying functional and anatomical success.

REFERENCES

1. Waelti S, Fischer T, Sturm V, Heckmann J. Combined hamartoma of the retina and retinal pigment epithelium - MRI features of a rare paediatric intraocular tumour. *BJR Case Rep.* 2020 Nov 17;7(2):20200077. doi: 10.1259/bjrcr.20200077. PMID: 33841897; PMCID: PMC8008464.
2. Konstantinidis L, Chamot L, Zografos L, Wolfensberger TJ. Pars Plana vitrectomy and epiretinal membrane peeling for vitreoretinal traction associated with combined hamartoma of the retina and retinal pigment epithelium (CHRRPE). *Klin Monbl Augenheilkd.* 2007 Apr;224(4):356-9. doi: 10.1055/s-2007-962840. PMID: 17458814.
3. Mariana Sgroi MD, Franco Benvenuto MD, Francisco Maldonado MD, Luis Diaz Gonzalez MD, Carlos Rugilo MD, Adriana Fandiño MD. Combined Hamartoma of the Retina and Retinal Pigment Epithelium (CHR-RPE) in a Baby. *Journal of Ophthalmology and Research* 4 (2021): 192-198.
4. Zhang X, Dong FT, Dai RP, Yu WH. [Clinical characteristics of suspected combined hamartoma of the retina and retinal pigment epithelium]. *Zhonghua Yan Ke Za Zhi.* 2009 May;45(5):406-11. *Chinese.* PMID: 19576062.