

# Myopic Traction Maculopathy- Current Concepts

Samya Singh, Sandeep Saxena\*

Department of Ophthalmology, King George's Medical University, Lucknow, India.

## Abstract

Myopic traction maculopathy, also known as myopic foveoschisis is seen in patients with pathological myopia due to differential stretching of the retina and choroid as the eye elongates. It can be associated with a lamellar or full-thickness macular hole. Optical Coherence Tomography is useful in diagnosis. Specific protocols for treatment are yet to be established and the visual prognosis continues to be poor.

**Keywords:** Pathological myopia, Myopic foveoschisis, Myopic traction maculopathy.

## INTRODUCTION

Pathological myopia is myopia of more than -6D or an axial length of 26 mm or more.<sup>1</sup> It is known to occur in about 2% of the world population. About 8 to 34% of these have myopic traction maculopathy (MTM), also known as myopic foveoschisis. Female to male ratio is about 3:1.

Takano and Kishi in 1999 first described foveoschisis. It is defined in eyes with posterior staphyloma as a split in the layers of retina at the fovea.<sup>2</sup>

## Pathogenesis

Elongation of eye in pathological myopia causes stretching of the three layers of the eye. Differential stretching of retina and choroid causes the retina to split up. The myopic eye elongates axially as well as in a plane tangential to retina.<sup>3</sup> MTM is a dynamic disease that slowly progresses over the years. Schisis first occurs in the inner retinal layers and then progresses gradually to the outer retinal layers. As the disease progresses, a lamellar macular hole can develop.<sup>4</sup> A full-thickness macular hole has also been reported in advanced cases of MTM.<sup>5</sup>

## Symptoms

Patients commonly present in the fifth or sixth decade with complaints of diminished vision, floaters, flashes of light, metamorphopsia, or scotoma.

## Diagnosis

Fundus examinations reveal signs of pathological myopia which include- a large with temporal crescent or peripapillary

thinning, background tessellations due to chorioretinal atrophy, lacquer cracks, Forster-Fuch spots, myopic choroidal neovascularisation, posterior staphyloma, myopic foveoschisis, lattice degeneration with or without hole, macular hole and retinal detachment (Figure 1).

## Role of Spectral Domain Optical Coherence Tomography (SD-OCT)

SD- OCT has made diagnosis and even classification of foveoschisis possible beyond any doubt (Figure 2).

MTM staging system (MSS) based on the OCT has been developed.<sup>6</sup>

Stage 1a: Inner-outer macular schisis with a normal foveal profile

Stage 1b: Inner-outer macular schisis with a lamellar macular hole

Stage 1c: Inner-outer macular schisis with a full-thickness macular hole

Stage 2a: Predominantly outer macular schisis with a normal foveal profile

Stage 2b: Predominantly outer macular schisis with a lamellar macular hole

Address for correspondence: Sandeep Saxena,  
Department of Ophthalmology, King George's Medical University, Lucknow, India.  
E-mail: sandeepsaxena2020@yahoo.com

© Authors, 2023. Open Access. This article is licensed under a Creative Commons Attribution 4.0 International License, which permits use, sharing, adaptation, distribution and reproduction in any medium or format, as long as you give appropriate credit to the original author(s) and the source, provide a link to the Creative Commons licence, and indicate if changes were made. The images or other third party material in this article are included in the article's Creative Commons licence, unless indicated otherwise in a credit line to the material. If material is not included in the article's Creative Commons licence and your intended use is not permitted by statutory regulation or exceeds the permitted use, you will need to obtain permission directly from the copyright holder. To view a copy of this licence, visit <https://creativecommons.org/licenses/by-nc-sa/4.0/>.



UP JOURNAL OF OPHTHALMOLOGY

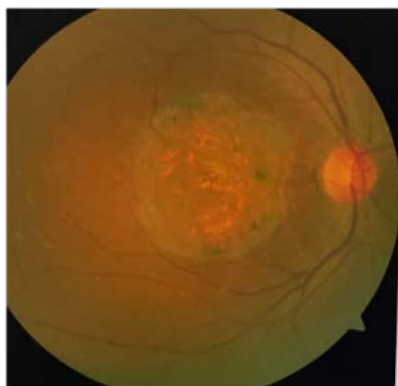
An Official Journal of Uttar Pradesh State Ophthalmological Society,  
UPSOS (Northern Ophthalmological Society, NOS)

p-ISSN: 2319-2062

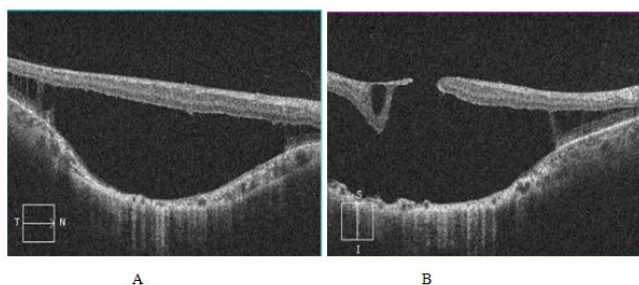
DOI: 10.56692/upjo.2023110204

**How to cite this article:** Singh S, Saxena S. Myopic Traction Maculopathy: Current Concepts. UP Journal of Ophthalmology. 2023;11(2): 48-49.

**Received:** 12-07-2023, **Accepted:** 08-08-2023, **Published:** 20-09-2023



**Figure 1:** Fundus photograph of a 43-year-old female with high myopia of -16 D both eyes and an axial length of 26.6 mm showing posterior staphyloma, pigmentary abnormalities, lacquer cracks and myopic foveoschisis.



**Figure 2:** SD-OCT images of the same patient mentioned above  
 A) Macular foveoschisis with foveal detachment can be seen along with posterior staphyloma and an extremely thin choroid  
 B) Macular foveoschisis with foveal detachment with full thickness macular hole, posterior staphyloma and extremely thin choroid is seen

Stage 2c: Predominantly outer macular schisis with a full-thickness macular hole

Stage 3a: Macular schisis detachment with a normal foveal profile

Stage 3b: Macular schisis detachment with a lamellar macular hole

Stage 3c: Macular schisis detachment with a full-thickness macular hole

Stage 4a: Macular detachment with a normal foveal profile

Stage 4b: Macular detachment with a lamellar macular hole

Stage 4c: Macular detachment with a full-thickness macular hole

Associated epiretinal abnormalities are indicated by a “+” sign.

## Management

Specific protocols for management are yet to be developed since the disease is rare.

Surgical options include pars plana vitrectomy (PPV), internal limiting membrane (ILM) peeling, and scleral buckling.

For eyes having a macular hole, the surgery of choice is PPV with ILM peeling.<sup>7</sup> Eyes having schisis and detachment can undergo a macular buckle to counter the perpendicular tractional force.<sup>8,9</sup> The macular buckle causes a shortening of the axial length of the eye at the posterior pole.<sup>10,11</sup>

Poor prognostic factors include foveal detachment, a full-thickness macular hole, high axial length, deep staphyloma, and choroidal thinning.<sup>12</sup>

## REFERENCES

- Guo X, Chen X, Li M, Li S, You R, Wang Y. Association between morphological characteristics of the optic disc and other anatomical features of the fundus in highly myopic eyes. *Eur J Ophthalmol.* 2021 Sep;31(5):2329-2338.
- Takano M, Kishi S. Foveal retinoschisis and retinal detachment in severely myopic eyes with posterior staphyloma. *Am J Ophthalmol.* 1999 Oct;128(4):472-6.
- Pugazhendhi S, Ambati B, Hunter AA. Pathogenesis and Prevention of Worsening Axial Elongation in Pathological Myopia. *Clin Ophthalmol.* 2020;14:853-873.
- Rino F, Elena Z, Ivan M, Paolo B, Barbara P, Federica R. Lamellar macular hole in high myopic eyes with posterior staphyloma: morphological and functional characteristics. *Graefes Arch Clin Exp Ophthalmol.* 2016 Nov;254(11):2141-2150.
- Ono T, Terada Y, Mori Y, Kataoka Y, Nakahara M, Miyata K. Spontaneous resolution of myopic foveoschisis and a macular hole with retinal detachment. *Am J Ophthalmol Case Rep.* 2019 Mar;13:143-146.
- Parolini B, Palmieri M, Finzi A, Besozzi G, Lucente A, Nava U, et al. The new Myopic Traction Maculopathy Staging System. *Eur J Ophthalmol.* 2021 May;31(3):1299-1312.
- Gui J, Ai L, Huang T. Vitrectomy with or without internal limiting membrane peeling for myopic foveoschisis. *BMC Ophthalmol.* 2020 Mar 04;20(1):83.
- Grewal PS, Seamone M, Greve M, Deveau A, Gupta RR. Internal Chandelier- assisted macular buckling for myopic foveoschisis. *Retin Cases Brief Rep.* 2022 Jul 01;16(4):532-535.
- Zhao X, Ma W, Lian P, Tanumiharjo S, Lin Y, Ding X, et al. Three-year outcomes of macular buckling for macular holes and foveoschisis in highly myopic eyes. *Acta Ophthalmol.* 2020 Jun;98(4):e470-e478.
- Parolini B, Frisina R, Pinackatt S, Gasparotti R, Gatti E, Baldi A, et al. Indications and results of a new l-shaped macular buckle to support a posterior staphyloma in high myopia. *Retina.* 2015 Dec;35(12):2469-82.
- Parolini B, Frisina R, Pinackatt S, Mete M. A new L-shaped design of macular buckle to support a posterior staphyloma in high myopia. *Retina.* 2013 Jul-Aug;33(7):1466-70.
- Kim CY, Kim MS, Kim KL, Woo SJ, Park KH. Prognostic Factors Related with Surgical Outcome of Vitrectomy in Myopic Traction Maculopathy. *Korean J Ophthalmol.* 2020 Feb;34(1):67-75.