

A Case of Berlin's Edema after Fire Cracker Injury

Rahul Navinchandra Bakhda

Ex-Assistant Professor, Amaltas Institute of Medical Science, Dewas, Madhya Pradesh, India

Abstract

A 22 year old medical student presented in ophthalmic out patient department with fire cracker injury. On examination, his right eye anterior segment was normal, and there was corneal edema with mild congestion in the left eye. Fundus examination revealed commotio retinae or Berlin's edema in left eye. Ultrasonography B scan was normal and OCT revealed Berlin's edema with images of specific retinal layers affected by commotio retinae. The case report describes corneal edema and Berlin's edema in detail. The case report also describes the importance of public awareness regarding the safe handling of firecrackers.

Keywords: Firecracker, Berlin's edema, Commotio retinae, Corneal edema, OCT.

INTRODUCTION

Fire crackers for celebrating all kinds of special occasions are a major cause of visual morbidity.^{1,2}Trauma ranges from mild conjunctivitis, corneal edema, corneal abrasion, and Berlin's edema to complete loss of eye. Corneal edema if appropriately treated, shows a good prognosis.³ A retinal condition commotio retinae due to ocular trauma was first described by Berlin in 1873 as Berlin's edema.⁴Differential diagnosis of Berlin's edema includes other traumatic retinal conditions such as choroidal rupture, purtscher retinopathy, traumatic macular hole, chorioretinitis sclopetaria and retinal detachment and fundus photography, OCT and USG B scan are done to confirm the diagnosis. Optical coherence tomography is of great value in the management of patients with Berlin's edema.OCT is a non-invasive technique that provides optical cross-sectional images of the retina and morphological information close to that obtained from histological studies and defines anatomic details of commotio retinae.⁵ We report an interesting case of corneal edema and Berlin's edema after firecracker injury.

Case Report

A 22 year old medical student presented to ophthalmic OPD in a tertiary care centre with a history of trauma by fire cracker in the left eye with sudden diminution of vision. Visual acuity in right eye was 6/6 and in left eye it was counting finger at 2 m distance. right eye anterior segment examination was unremarkable.

There was corneal edema in left eye with mild congestion. Flourescein staining was negative and there was no corneal epithelial damage. Gonioscopy in left eye was normal. Ophthalmoscopy revealed normal fundus in the right eye and in the left eye it revealed retinal whitening with macular discoloration suggestive of macular edema. Fundus photograph of the left eye was taken along with an ultrasonography B Scan, and OCT examination was done.

Ultrasonography of the LE was done in Figure 1 and was normal. Fundus photograph of left eye Figure 2 depicts retinal whitening and macular discoloration suggestive of macular edema or commotio retinae.

OCT of the left eye in Figure 3 shows macular OCT with retinal thickening with disruption of retinal layers with retinal edema. The patient was prescribed antibiotic eye drops TDS, NSAID eye drops TDS, low-dose prednisolone eye drops BD and lubricating eye drops. The patient was given Prednisolone 20 mg 2 tablets after breakfast for seven day, along with antacids. The patient was called for follow-up after 7 days and showed marked improvement of reduced corneal edema and Berlin's edema. Berlin's edema subsided after 1 month, leaving no visual sequelae. The patient's vision on follow-up

Address for correspondence: Rahul Bakhda,
Amaltas Institute of Medical Science, Dewas, Madhya Pradesh, India
E-mail: bakhdaeyecare@rediffmail.com

©Authors,2023Open AccessThis article is licensed under a Creative Commons Attribution 4.0 International License, which permits use, sharing, adaptation, distribution and reproduction in any medium or format, as long as you give appropriate credit to the original author(s) and the source, provide a link to the Creative Commons licence, and indicate if changes were made. The images or other third party material in this article are included in the article's Creative Commons licence, unless indicated otherwise in a credit line to the material. If material is not included in the article's Creative Commons licence and your intended use is not permitted by statutory regulation or exceeds the permitted use, you will need to obtain permission directly from the copyright holder. To view a copy of this licence, visit <https://creativecommons.org/licenses/by-nc-sa/4.0/>.

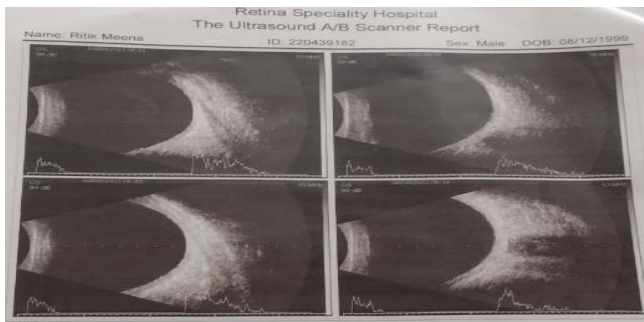


Figure 1: Normal USG B scan

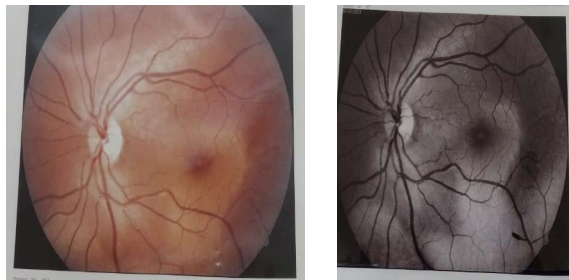

Figure 2: Fundus photograph showing retinal whitening and retinal discolouration

was 6/6 and there were no pigmentary changes on the macula. The corneal edema was also resolved.

DISCUSSION

The firecrackers used for celebrative purposes are associated with firework casualties. The most common anterior segment findings were conjunctival or corneal foreign bodies and corneal edema, whereas Berlin's was the most common posterior segment findings. Firecracker injuries significantly impact the quality of life and result in temporary or even permanent visual inability. A potential long-term disability could have both critical economic consequences and a relevant impact on the public health system. The benefits of trauma registries for better patient care and for developing preventive measures have been widely advocated. Use of ocular protective devices and public education will go in a long way to solve the magnitude of firecracker injuries.⁶

Corneal edema if not associated with descents detachment has a good prognosis. Topical steroids are effective and useful in reducing anterior segment inflammation and corneal edema.

Berlin's edema is an acute traumatic maculopathy also called commotio retinae. It was first described by Berlin in 1873. Comotio retinae presents grey-white opacification of retina, intra-retinal hemorrhages and retinal pigment disruption. Optical coherence tomography is of great value in the management of patients with posterior segment trauma. It defines anatomic details to confirm the diagnosis and better explains the pathogenesis, particularly in acute traumatic maculopathy. Pulido *et al.* has reported that the breakdown of a blood-retinal barrier as one of the possible mechanisms

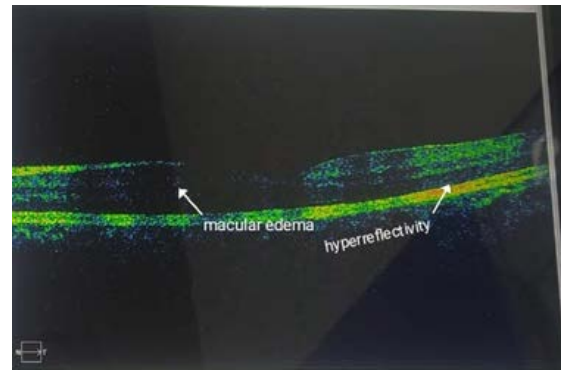


Figure 3: Macular OCT of LE showing retinal thickening with disorganization of retinal layers suggesting Berlin's edema.

for Berlin's edema.⁷ OCT helps in the visualization of intraretinal morphology allowing for the examination of the external limiting membrane and Inner Segment (IS)/Outer Segment(OS) junction. Mansour *et al.* showed that the major site of injury in commotio retinae is likely at the photoreceptor outer segment-retinal pigment epithelium junction⁸. OCT results depicted commotio retinae showed increased reflectivity of the photoreceptor's outer segment of the eye.⁹ In our case, OCT shows an increase in retinal thickening and retinal edema. There is no approved treatment for commotio retinae, the condition resolves over the course of few weeks to a few months. Steroids have been considered as a treatment option, high dose IV steroids have anecdotally been shown to reduce retinal swelling and improve visual acuity.^{10,11} In our case oral prednisolone was used for one week with miraculous effect along with topical low-dose prednisolone eye drops and visual acuity improved to 6/6 after one month. Bolus of Solumedrol for three successive days and corticosteroid eye drops with progressive degression has been successfully used in Berlin's edema.⁵ Clinicians should perform gonioscopy of the angle to rule out angle recession and should be aware of the fact that angle recession can develop months to years after initial trauma and glaucoma testing be mandated in future. Berlin's edema has a favorable prognosis but in more severe cases, the patient may be left with permanent macular damage resulting in visual impairment and paracentral scotoma.

CONCLUSION

Restricting the personal use of firecrackers is a proven method to reduce the number of firecracker-related morbidity, personal protective devices and community awareness has to be done. Corneal edema has a favorable prognosis and OCT can be a useful adjunct for monitoring the progress of Berlin's edema.

ACKNOWLEDGMENTS

I would like to acknowledge Dr. Vandana Telgote madam, HOD and Professor of Ophthalmology, AIMS, Dewas.

I would like to thank Dr. Arun Bhargava, Retina Speciality Hospital, Indore for Ultrasonography B-scan, Optical Coherence Tomography and Fundus Photography images.

FINANCIAL SUPPORT AND SPONSORSHIP

Nil

CONFLICT OF INTEREST

Nil

REFERENCES

1. Turgut F, Bograd A, Jeltsch B, Weber A, Schwarzer P, Ciotu IM, Amaral J, Menke MN, Thommen F, Tandogan T, Tappeiner C. Occurrence and outcome of firework-related ocular injuries in Switzerland: A descriptive retrospective study. *BMC ophthalmology*. 2022 Jul 7;22(1):296.
2. Wisse RP, Bijlsma WR, Stilma JS. Ocular firework trauma: a systematic review on incidence, severity, outcome and prevention. *British journal of ophthalmology*. 2010 Dec 1;94(12):1586-91.
3. Costagliola C, Romano V, Forbice E, Angi M, Pascotto A, Boccia T, Semeraro F. Corneal oedema and its medical treatment. *Clinical and Experimental Optometry*. 2013 Nov 1;96(6):529-35.
4. Berlin R. Zur sogenannten Commotio retinaw. *Klin Mbl Augenheilk*. 1873;11:42-78.
5. Chabbar I, Serghini L, Hajji Z, Berraho A. Commotio Retinae after Severe Blunt Eye Trauma.
6. Gupta SK, Shadab M, Verma D, Sharma P, Agrawal S. Case Series of Ocular Injury with Firecracker During Diwali in North India. *UP Journal of Ophthalmology*. 2022 Dec 14;10(01):20-4.
7. Pulido JS, Blair NP. The blood-retinal barrier in Berlin's edema. *Retina*. 1987 Dec 1;7(4):233-6.
8. Mansour AM, Green WR, Hogge C. Histopathology of commotio retinae. *Retina*. 1992 Jan 1;12(1):24-8.
9. Meyer CH, Rodrigues EB, Mennel S. Acute commotio retinae determined by cross-sectional optical coherence tomography. *European journal of ophthalmology*. 2003 Nov;13(9-10):816-8.
10. https://eyewiki.aao.org/Commotio_Retinae
11. Mendes S, Campos A, Beselga D, Campos J, Neves A, Castro Sousa JP. Traumatic maculopathy 6 months after injury: a clinical case report. *Case reports in ophthalmology*. 2014 Apr 1;5(1):78-82.
12. Chabbar I, Serghini L, Hajji Z, Berraho A. Commotio Retinae after Severe Blunt Eye Trauma.