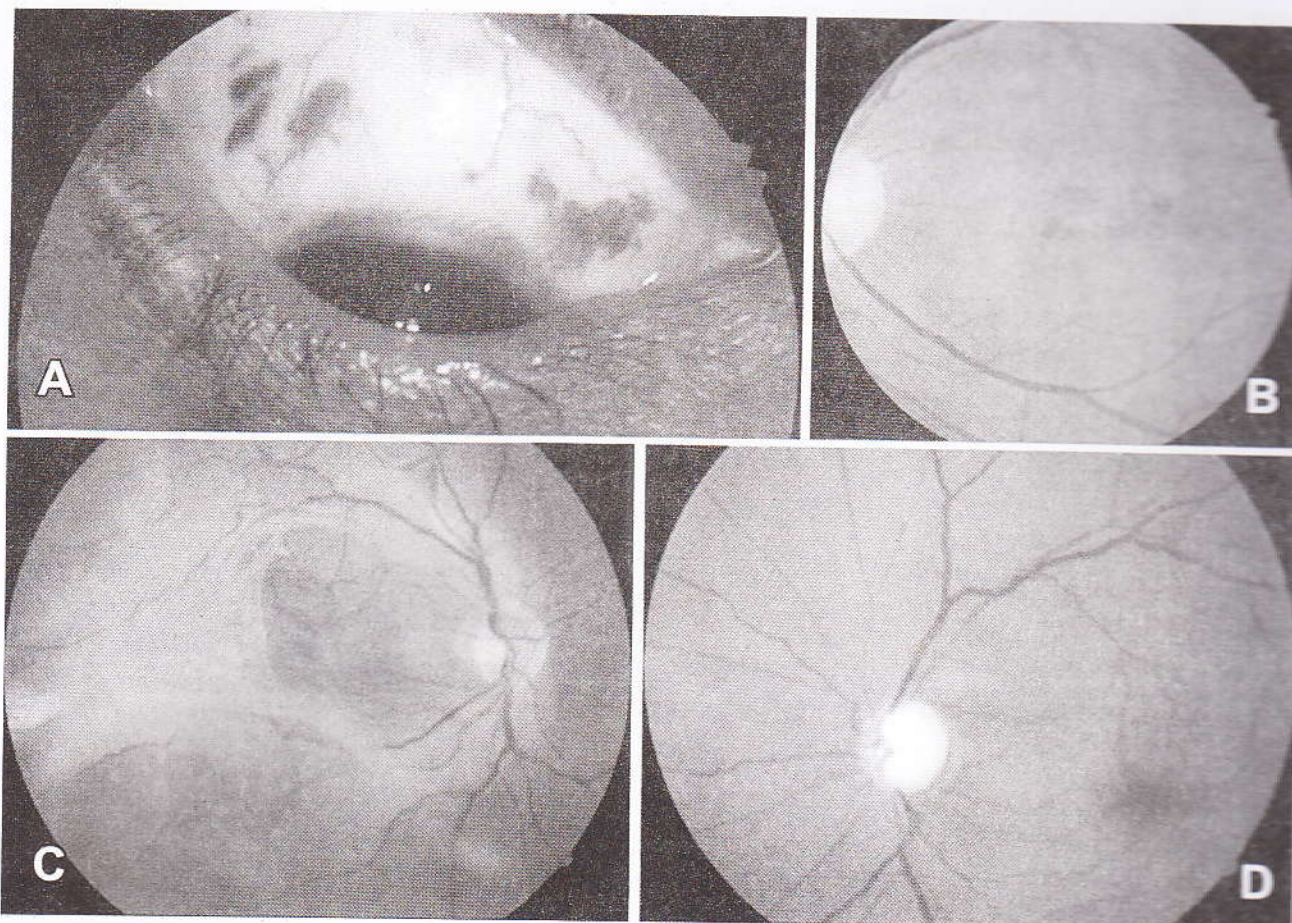


Answer to Ophthalmic Quiz - 3



A Nevus

B Sick RPE

C Epimacular Membrane

D Glaucomatous Optic Atrophy

The Lucky Winner of this is **DR. SHUBHAM ROY**, Agra
He would receive a Certificate from our society.