

Ocular Manifestations in Psoriatic Arthritis: A Case Report

Ruchika Agarwal, Harnoor Jot, Sadaf Khan*, Pallavi Dhawan, Namrata

Department of Ophthalmology, Rama Medical College, Mandhna, Kanpur, Uttar Pradesh, India

INTRODUCTION

Psoriasis is an immune-mediated, chronic inflammatory disease that primarily affects the skin. It is associated with numerous comorbidities, including psoriatic arthritis (PsA), cardiovascular disease, depression, diabetes, inflammatory bowel disease, and ocular diseases. A complex cascade involving several cytokines and immune cells- including TNF, IL-17, IL-22, and IL-23- contributes to the development of psoriasis. Psoriatic arthritis (PsA) is the inflammatory arthritis linked to psoriasis. Typically, the disease first manifests as skin lesions, which are later accompanied by articular symptoms. Research indicates that the incidence rate of ocular involvement ranges from 10 to 58%. Meibomian gland disorders and ocular conditions such as blepharitis, conjunctivitis, dry eye, keratitis, uveitis, and cataracts have been frequently reported. Dry eye disease may stem from systemic inflammatory disorders like psoriasis, where chronic inflammation impairs lacrimal gland function and tear film quality.

The most commonly mentioned subtype of psoriasis-related anterior uveitis is non-granulomatous. Both uveitis and dry eye can significantly impact quality of life and require management through a multidisciplinary approach.

Case report

A 14-year-old boy arrived at our outpatient clinic with a 15-day history of redness, burning, excessive watering, discharge, and swelling in both eyes. He also reported that his right eye's vision had been worse than his left eye's for 10 days.

His visual acuity was 6/60 in the right eye with a pinhole 6/24, 6/9 in the left eye with a pinhole 6/6P in the left eye. Intraocular pressure was measured with the help of a Goldman applanation tonometer in the right eye at 15 mm hg and left eye, was 11 mm hg.

On slit lamp examination, both the eyelids were swelled up with matted lashes, B/E conjunctiva was congested, and there was an epithelial defect in the right cornea which on about 3*4 mm in size at 4 o'clock position, extended towards the center, with diffuse haziness present around the defect, with keratic

precipitates present over the peri central along with a stain positive ulcer and in left eye the cornea was normal with had few keratic precipitates.

B/E anterior chamber depth was normal with signs of uveitis have cells +2, flare+1 in the right eye and cells +1, flare +2 in the left eye. B/E Lens was clear. B/E vitreous was normal. B/E fundus was normal.

For additional assessment, we used the Schirmer I test, which involved placing a 5 x 35 mm paper strip (Schirmer strips) to the lower temporal lid edge without anesthetic. A value of 5 mm in the left eye and 6 mm in the right eye after 5 minutes was considered abnormal.

Tear film breakup time (TBUT), 1% fluorescence was applied to the eye, and the average of three consecutive breakup times (manually determined with a stopwatch) was calculated (Figures 1 and 2). Time was 4 seconds in the right eye and 6 seconds in the left eye (Figures 3 and 4). In <10 seconds was considered abnormal.

A reddish-white raised patch over the lower back associated with itching since 7 years of age was also observed; the lesion subsides on taking medication (Figure 5).

Bilateral knee joint swelling and bilateral hip joint pain were present for 30 days, which gradually progressed to bilateral knee and ankle pain with swelling of the interphalangeal joints (Figure 6), which was relieved by taking medication. The patient had similar episodes of redness and pain in both eyes in the past.

The patient also had similar complaints in the past at the ages of 7 and 10 years, which were relieved by taking medication. There was a similar complaint reported in the younger sibling.

Address for correspondence: Sadaf Khan,

Department of Ophthalmology, Rama Medical College, Mandhna, Kanpur, Uttar Pradesh, India.

E-mail: sadafkhan1105@gmail.com



UP JOURNAL OF OPHTHALMOLOGY

An Official Journal of Uttar Pradesh State Ophthalmological Society,
UPSOS (Northern Ophthalmological Society, NOS)

p-ISSN: 2319-2062

DOI: 10.56692/upjo.2025130106

© UPJO, 2025 Open Access This article is licensed under a Creative Commons Attribution 4.0 International License, which permits use, sharing, adaptation, distribution and reproduction in any medium or format, as long as you give appropriate credit to the original author(s) and the source, provide a link to the Creative Commons licence, and indicate if changes were made. The images or other third party material in this article are included in the article's Creative Commons licence, unless indicated otherwise in a credit line to the material. If material is not included in the article's Creative Commons licence and your intended use is not permitted by statutory regulation or exceeds the permitted use, you will need to obtain permission directly from the copyright holder. To view a copy of this licence, visit <https://creativecommons.org/licenses/by-nc-sa/4.0/>.

How to cite this article: Agarwal R, Jot H, Khan S, Dhawan P, Namrata. Ocular Manifestations in Psoriatic Arthritis: A Case Report. UP Journal of Ophthalmology. 2025;13(1): 26-28.

Received: 05-02-25, **Accepted:** 21-03-25, **Published:** 30-04-25

Systemic steroids (Omnacortil) were given for 3 days, systemic antibiotics (Ciplox) for 5 days, systemic anti-inflammatory drugs (Zerodol-SP) were given for 5 days with topical steroid (Prednisolone) 2 hourly, topical antibiotics (Moxifloxacin) 2 hourly, topical cycloplegic (Homide) twice daily, topical lubricants (carboxymethylcellulose) 2 hourly with topical antiviral (Acyclovir) drug 3 times daily. He was reviewed after 1 week, and he got symptomatic relief and the defect on the cornea healed, and vision also improved.

The Orthopedic and Dermatology departments handled treatment for other systemic problems.

The dermatology department gave a methotrexate test dose of 5 mg and a tapering dose is given for a long time, with folic acid 5 mg once daily 5 mg once daily for 5 days. Ceramides containing lotion are given to apply on the skin lesion twice daily. A skin biopsy is sent from the lesion.

After a complete evaluation with other departments, the diagnosis was both eyes with chronic anterior uveitis with dry eye with anterior uveitis associated with psoriatic arthritis.

DISCUSSION

Psoriasis is a chronic inflammatory dermatological condition known for its systemic implications, including ocular manifestations. Among these, dry eye and uveitis are notable, with a prevalence ranging from 10 to 58% in psoriatic patients. These complications can affect almost all ocular structures, often contributing to significant morbidity if left undiagnosed or mismanaged. Uveitis typically presents as anterior and non-granulomatous in nature, frequently associated with HLA-B27 positive, whereas dry eye, in particular, is characterized by decreased tear production, unstable tear coatings, and associated local inflammation.^{11,12}

Misdiagnosis or delayed diagnosis is a frequent challenge, particularly in younger male patients, as the symptoms of ocular involvement may be subtle initially or attributed to other benign conditions such as conjunctivitis or allergies. This delay is compounded by limited access to specialized care for patients from low socioeconomic backgrounds. In such populations, systemic conditions like psoriasis and psoriatic arthritis often remain underdiagnosed due to financial constraints and lack of awareness, further delaying intervention for associated ocular conditions.¹³

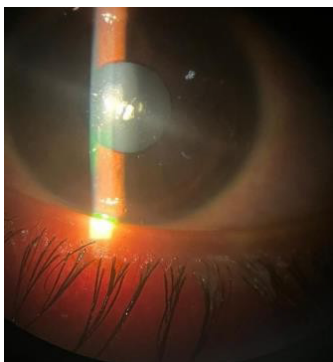


Figure 1: Cells and flare in AC, fluorescence in left eye

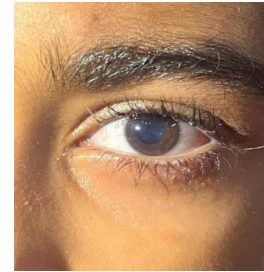


Figure 2: Congestion in conjunctiva and matted eye lashes

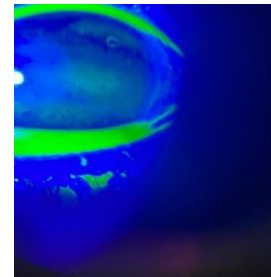


Figure 3: TBUT 1% fluorescence in left eye

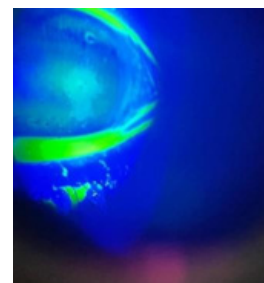


Figure 4: TBUT 1% fluorescence in right eye

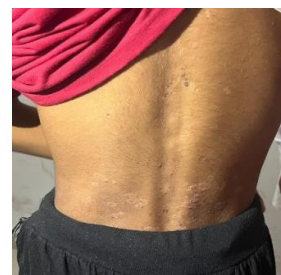

Figure 5: Reddish-white raised patch over the lower back

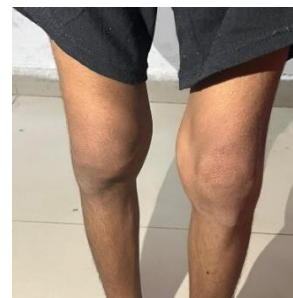

Figure 6: Bilateral knee joint swelling

Our case highlights a 14-year-old male patient presenting with chronic anterior uveitis and dry eye. The patient's history revealed recurrent episodes of joint pain and skin lesions since the age of seven, suggestive of psoriatic arthritis. Despite clear clinical indicators, these manifestations were not adequately addressed until the development of ocular symptoms. This underlines the critical need for multidisciplinary screening in young patients with psoriasis or psoriatic arthritis to prevent complications like visual impairment.^{14,15}

The increased incidence of psoriatic arthritis and its ocular manifestations in younger males may reflect genetic predispositions, such as the presence of HLA-B27, and environmental factors, including socioeconomic status and healthcare access. Studies have reported a male preponderance in psoriatic arthritis with ocular involvement, further emphasizing the need to prioritize early detection and treatment in this demographic. According to Chandran *et al.*, psoriatic arthritis is more common in men, and ocular involvement can occur frequently in this group of people.

Singh *et al.* also highlighted that up to 75% of uveitis cases in psoriatic arthritis are associated with HLA-B27 positivity, predominantly presenting as anterior uveitis.^{16,17}

Additionally, poor hygiene and living conditions, often associated with low economic status, may exacerbate ocular complications by increasing the risk of secondary infections and delaying the recognition of underlying inflammatory processes. This highlights the importance of community-level interventions to educate patients and improve access to affordable healthcare.¹⁸

When psoriatic arthritis patients' dry eye and uveitis are not properly treated, serious consequences might result, which include corneal scarring and irreversible vision loss. Comprehensive management requires collaboration between dermatologists, rheumatologists, and ophthalmologists to address the systemic and ocular aspects of the disease. Early screening, especially in high-risk groups such as younger males and those from lower socioeconomic backgrounds, is vital for reducing morbidity and improving outcomes.¹⁹

In conclusion, this case underscores the importance of heightened vigilance for ocular manifestations in psoriatic arthritis, particularly in younger males and economically disadvantaged populations. To avoid long-term problems and enhance patients' quality of life, systemic inflammation must be treated with targeted therapy in addition to early detection and treatment of ocular diseases.

CONCLUSION

Dry eye and uveitis are prevalent ocular manifestations in individuals with psoriasis. Dermatologists need to be aware of this possible comorbidity and collaborate closely with ophthalmologists in order to treat psoriasis patients comprehensively. Screening of patients with greater severity of psoriasis would help in the early management of such problems.

REFERENCES

- deLima FBF, Abalem MF, Ruiz DG, Gomes B, deAzevedo MNL, Moraes HV, *et al.* Prevalence of eye disease in Brazilian patients with psoriatic arthritis. *Clinics (Sao Paulo)*. 2012;67(3):249–53.
- Moll JM, Wright V. Psoriatic arthritis. *Semin Arthritis Rheum*. 1973;3(1):55–78.
- Griffiths CE, Barker JN. Pathogenesis and clinical features of psoriasis. *Lancet* 2007;370:263–71.
- Oliveira MF, Rocha BO, Duarte GV. Psoriasis: classical and emerging comorbidities. *An Bras Dermatol*. 2015;90:9–20.
- Boehncke WH, Schön MP. Psoriasis. *Lancet*. 2015;386(9997):983–94.
- Jamshidi F, Bouzari N, Seirafi H, Farnaghi F, Firooz A. The prevalence of psoriatic arthritis in psoriatic patients in Tehran, Iran. *Arch Iran Med*. 2008;11(2):162–5.
- Queiro R, Sarasqueta C, Belzunegui J, Gonzales C, Figueroa M, Torre-Alonso JC. Psoriatic Spondyloarthritis: A comparative study between HLA-B27 positive and HLA-B27 negative disease. *Semin Arthritis Rheum*. 2002;31(6):413–8.
- Kilic B, Dogan U, Parlak AH, Goksugur N, Polat M, Serin D, *et al.* Ocular findings in patients with psoriasis: Ocular findings in psoriasis. *Int J Dermatol* 2013;52:554–9.
- Rehal B, Modjtahedi BS, Morse LS, Schwab IR, Maibach HI. Ocular psoriasis. *J Am Acad Dermatol*. 2011;65(6):1202–12.
- Chaiyabutr C, Ungprasert P, Silpa-Archa N, Wongpraparut C, Chularojanamontri L. Psoriasis and Risk of Uveitis: A Systematic Review and Meta-Analysis. *Biomed Res Int*. 2020;2020:9308341. doi:10.1155/2020/9308341.
- Rehal B, Modjtahedi BS, Morse LS, Schwab IR, Maibach HI. Ocular psoriasis. *Journal of the American Academy of Dermatology*. 2011;65(6):1202–1212. doi:10.1016/j.jaad.2010.10.032.
- Aryanian Z, Shirzadian A, Hatami P, *et al.* Ocular manifestations of psoriasis: An inflammatory disease beyond the skin. *Journal of General and Family Medicine*. 2023;24(1):45–49. doi:10.1002/jgf2.576.
- Cruz NFS, Brandão LS, Cruz SFSD, *et al.* Ocular manifestations of psoriasis. *Arquivos Brasileiros de Oftalmologia*. 2018;81(3). doi:10.5935/0004-2749.20180044.
- Singh A, Kumar P, Sinha P, *et al.* An observational study on ocular manifestations in patients of psoriasis in a tertiary care hospital in western India. *Med J Armed Forces India*. 2022;78(Suppl 1):S186–S193. doi:10.1016/j.mjafi.2020.12.019.
- Shah RD, Satapathy J, Panigrahi PK, Kar BR, Mohapatra RC. Ocular manifestations of psoriasis: A case-control study. *TNOA J Ophthalmic Sci Res*. 2021;59:164.
- Chandran NS, Greaves M, Gao F, *et al.* Psoriasis and the eye: Prevalence of eye disease in Singaporean Asian patients with psoriasis. *J Dermatol*. 2007;34:805–10.
- Abbagani S, Kamath YS, Nayak S. A study on ocular morbidity among patients with psoriasis visiting a tertiary care hospital in Karnataka, southern India. *Ocul Immunol Inflamm*. 2019;27:531–4.
- Her Y, Lim JW, Han SH. Dry eye and tear film functions in patients with psoriasis. *Jpn J Ophthalmol*. 2013;57:341–6.
- Menter A, Gottlieb A, Feldman SR, *et al.* Guidelines of care for the management of
- psoriasis and psoriatic arthritis. *Journal of the American Academy of Dermatology*. 2008;58(5):826–850. doi:10.1016/j.jaad.2008.02.039.