

Canalicular Reconstruction Using a 24-Gauge Intravenous Cannula : A Case Report

Niraj Kumar Yadav¹, Eesha Agarwal², Sanket Vinod Sadaphale³

^{1,2,3}Department of Ophthalmology, Dr KNS Memorial Institute of Medical Sciences, Barabanki, Uttar Pradesh.

Abstract

Purpose : To describe a simple, inexpensive technique for canalicular reconstruction using a 24-gauge (24G) intravenous (IV) cannula as a temporary monocanalicular stent after traumatic laceration.

Case Presentation : A 12-year-old child with an isolated laceration of the lower canaliculus underwent primary repair utilizing a trimmed 24-G IV cannula as a stent. The stent was in place for 12 weeks before being removed during a clinic visit. At the 6-month follow-up, the patient was asymptomatic, demonstrated patent irrigation, and reported no episodes of epiphora.

Discussion : After performing canalicular repair, the punctal position, canalicular support, and patency were preserved without any signs of infection or extrusion. There was neither epiphora nor ocular irritation observed during the 6-month follow-up period. This case report is corroborated by multiple other studies.

Conclusion : A standard 24G intravenous cannula serves as an effective and cost-efficient alternative for canalicular repair in scenarios where commercial stents are either inaccessible or prohibitively priced. The clinical outcomes observed in this application are comparable to those associated with traditional silicone stents.

Keywords : Canalicular laceration, Canalicular Repair, 24G IV Canula, Canalicular intubation.

Introduction

An innovation is key to paving surgical advancements and success stories. The limitation of resources catalyzes the conception of innovation. Trauma can lead to unpredictable changes in anatomy, consequently compromising the physiology of the involved organ to an unprecedented extent. Traumatic canalicular lacerations are commonly managed with monocanalicular or bicanalicular silicone intubation to maintain luminal patency during healing. Access and cost, however, may limit the availability of commercial devices (e.g., Mini-Monoka, Masterka, Crawford/Ritleng).¹ Low-cost substitutes, including segments of IV/venous catheters, have been reported for canalicular intubation and related lacrimal procedures.² We came across a case of right lower eyelid laceration with canalicular injury. The challenges encountered were the pediatric age of the patient, nonavailability of conventional stents/implants, and in

inserting the innovative malleable plastic implant through the torn lacrimal passage with a favorable functional outcome.

Case Report

A 12-year-old male presented 10 hours after sustaining an injury to the right medial lower eyelid caused by a motorcycle mirror. He reported experiencing tearing and blood-tinged discharge but denied any loss of consciousness, as well as any nasal or ear bleeding. Upon examination, the right lower lid exhibited a 7-mm full-thickness medial laceration,

Address for correspondence : Dr. Niraj Kumar Yadav
Dr KNS Memorial Institute of Medical Sciences, Barabanki, Uttar Pradesh.
E-mail : dr.nirajyadav@gmail.com

© UPJO, 2025 Open Access This article is licensed under a Creative Commons Attribution 4.0 International License, which permits use, sharing, adaptation, distribution and reproduction in any medium or format, as long as you give appropriate credit to the original author(s) and the source, provide a link to the Creative Commons licence, and indicate if changes were made. The images or other third party material in this article are included in the article's Creative Commons licence, unless indicated otherwise in a credit line to the material. If material is not included in the article's Creative Commons licence and your intended use is not permitted by statutory regulation or exceeds the permitted use, you will need to obtain permission directly from the copyright holder. To view a copy of this licence, visit <https://creativecommons.org/licenses/by-nc-sa/4.0/>.

accompanied by complete tearing of the right lower canaliculus (Figure 1). The punctal opening remained intact but was displaced from its normal anatomical position. The alignment of the lid margin was otherwise preserved, with no evidence of medial canthal tendon avulsion. The best-corrected visual acuity for the right eye was 6/6. A dye disappearance test revealed a delay on the right side, and irrigation through the upper punctum resulted in reflux from the lacerated lower canaliculus. The orbital margin was intact, and extraocular movements were full in all gazes. There were no signs of globe injury or naso-orbital fracture, and the examination of the left eye was within normal limits. After a comprehensive history and examination, written informed consent was obtained, and primary repair was successfully performed under general anesthesia within 12 hours of the

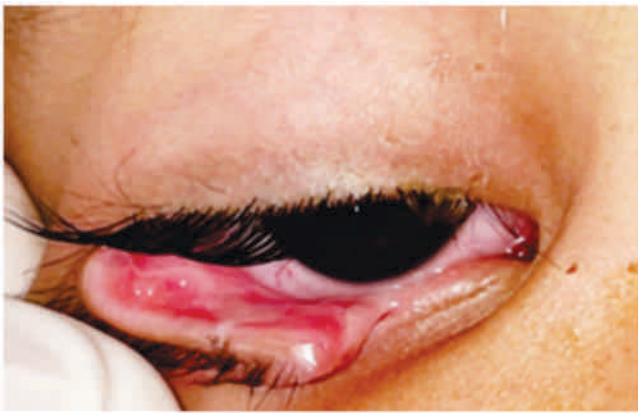

Figure 1: Preoperative image depicting a laceration of the right lower eyelid, characterized by a full-thickness tear of the lower canaliculus. The lower punctum is evident and is positioned abnormally, deviating from its typical anatomical location

injury.

Surgical Technique & Follow-up

The wound was irrigated and thoroughly cleaned. Using loupe magnification and probing, the proximal canaliculus was identified. A standard 24G IV cannula was trimmed to approximately 25–30 mm, with the bevel removed and the edges rounded. The cannula was then advanced through the lower punctum into the proximal canaliculus and across the laceration, confirming patency via irrigation. The canalicular mucosa was approximated with three 7-0 polyglactin sutures positioned around the cannula. Both cut ends were primarily sutured using anterior, posterior, and superior pericanalicular sutures, followed by a layered closure. The stent was secured to the lid margin for stability (Figure 2). For post-operative care, topical antibiotics, oral antibiotics, lubricants, and eyelid hygiene were prescribed. Follow-ups were conducted on postoperative days 1, 7, 4 weeks, and at 12 weeks when the stent was removed without complications. At the 6-month mark, the patient reported no epiphora, and syringing

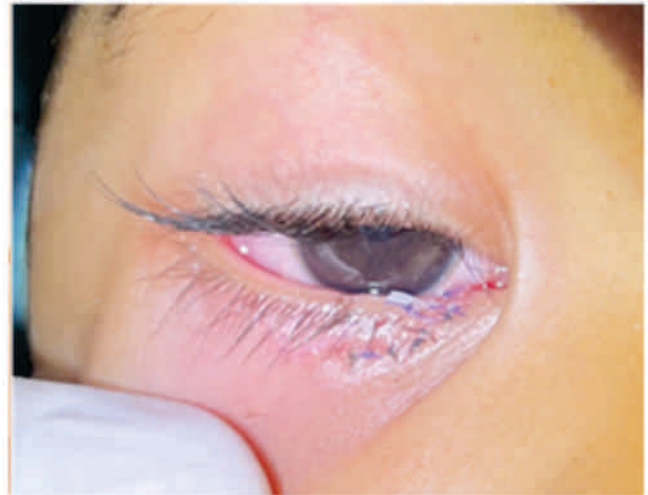


Figure 2: The image taken on post-operative day 1 demonstrates that the contour of the right lower lid is well-preserved. A portion of the 24-gauge cannula is in the lower canaliculus, while the external part is secured to the anterior aspect of the lower lid. This setup not only stabilizes the cannula but also prevents it from rubbing against the cornea.

confirmed free flow into the nasal cavity.

Discussion

Eyelid lacerations, whether partial or full-thickness, represent a notable category of facial trauma, particularly in children and young adults. These injuries may occur alongside other ocular complications, including corneal lacerations, disruption of the lacrimal drainage system, foreign bodies, open globe injuries, or orbital fractures.³ Currently, there are no established protocols for the repair of the associated lacrimal passage or the surgical techniques to be employed. While commercial monocanalicular stents demonstrate a high success rate in the repair of canalicular lacerations, factors such as cost and availability can pose challenges. In response, low-cost alternatives utilizing venous or IV catheter materials have been documented for the repair of canalicular stenosis, obstruction, and trauma, showing promising outcomes.^{4,5} A study indicated that innovative, cost-effective approaches to canalicular stenting may be more advantageous than using a standard monocanalicular stent. In this method, a 20G silicon rod is employed to reconstruct the canalicular laceration, demonstrating reasonable success. This approach is particularly relevant for developing countries, where many underprivileged individuals face challenges in accessing affordable healthcare.⁶ A recent study indicates that utilizing a 24G intravenous cannula offers a cost-effective approach to canalicular tear repair, with easy accessibility and no additional expenses for patients. This technique, associated with minimal complications, can be effectively implemented in government healthcare settings due to its affordability.⁷ Another study recommends the use of a needle within an IV cannula as a guiding mechanism to advance through the entire

length to the sac area. However, based on our experience and perspective, we believe this technique presents a risk of creating multiple false passages in emergency care settings.⁸ A recent study highlights an innovative application of venous catheters as stents for the treatment of acquired punctal and canalicular stenosis. This approach appears to be remarkably straightforward, demonstrating a high degree of safety, ease of repetition, and a less invasive nature. It offers a promising solution for patients with this condition, minimizing discomfort while enhancing treatment efficacy.⁹ In a study, the 26G IV cannula catheter has proven to be an effective and economical alternative for canalicular lacerations, demonstrating excellent surgical success. This technique can be used as an alternative to conventional repair procedures.¹⁰ The potential limitations of our technique include auto-extrusion, implant loss, granuloma formation, infection, and corneal rubbing caused by the implant. However, these issues can be easily mitigated by suturing the implant above the lash line, as outlined in the methodology. The innovation of utilizing a 24G IV cannula catheter as a stent for monocanalicular repair presents a significant and cost-effective alternative to traditional monocanalicular stents. This advancement is particularly relevant and promising for developing countries, where a large portion of the population lacks access to affordable healthcare. Further research involving a larger sample size could validate this technique as an alternative to conventional repair methods.

Conclusion

In situations where commercial lacrimal stents are not accessible, utilizing a 24-G intravenous cannula provides a cost-effective alternative for canalicular reconstruction following traumatic injury. This approach has demonstrated favorable functional outcomes in cases undertaken.

Patient Consent

Written informed consent for treatment and publication of de-identified clinical details and photos (if any) was obtained from the patient in accordance with institutional policy.

Ethics

This report adheres to the principles of the Declaration of Helsinki. Institutional review was not required for a single de-identified case report.

References

1. Lin CH, Wang CY, Shen YC, Wei LC. Clinical Characteristics, Intraoperative Findings, and Surgical Outcomes of Canalicular Laceration Repair with Monocanalicular Stent in Asia. *J Ophthalmol.* 2019;2019:5872485.
2. Aytoğan H, Karadeniz Uğurlu Ş. Evaluation of anatomical and functional outcomes in patients undergoing repair of traumatic canalicular laceration. *Ulus Travma Acil Cerrahi Derg.* 2017;23(1):66–71.
3. Cho SH, Hyun DW, Kang HJ, Ha MS. A simple new method for identifying the proximal cut end in lower canalicular laceration. *Korean J Ophthalmol.* 2008;22:73–6. doi: 10.3341/kjo.2008.22.2.73.
4. Agrawal R, et al. Comparative study of Mini-Monoka stenting and 24G IV cannula stenting in canalicular laceration. *Int J Life Sci Pharma Res.* Vol. 13, No. 6, June 2024. DOI: 10.69605/ijlbpr_13.6.2024.70
5. Singh S, Ganguly A, Hardas A, Tripathy D, Rath S. Canalicular lacerations: Factors predicting outcome at a tertiary eye care centre. *Orbit.* 2017;36:13–8. doi: 10.1080/01676830.2017.1279646.
6. Chatterjee S, Rath S, Roy A, Shrestha E. 20G silicone rod as monocanalicular stent in repair of canalicular lacerations: Experience from a tertiary eye care centre. *Indian J Ophthalmol.* 2013;61:585–6. doi: 10.4103/0301-4738.121080.
7. Anuradha A, Kulkarni VM, Vidya DM, Ranjitha C. S. A study of modified and economical approach to canalicular tear using IV cannula in a tertiary care centre. *Int J Ocul Oncol Oculoplasty.* 2018;4:169–71.
8. Shah SM, Shah MA, Patel KB, Singh RU. Innovative cost-effective method to repair lacrimal canaliculi laceration – Finding proximal end and stent. *GMS Ophthalmol Cases.* 2019;9:Doc20. doi: 10.3205/oc000109.
9. Meduri, Alessandro PhD, MD; et al. The Use of a Venous Catheter as a Stent for Treatment of Acquired Punctal and Canalicular Stenosis. *Journal of Craniofacial Surgery* 30(8):p 2544-2545, November-December 2019. | DOI: 10.1097/SCS.00000000000005743.
10. Sharma, Vikas; et al. Canalicular repair in an infant with a simple modification in implantation technique of a conventional innovative implant for canalicular stenting. *Oman Journal of Ophthalmology* 18(1):p 66-69, Jan–Apr 2025. | DOI: 10.4103/ojo.ojo_206_24.