

# Post-Collagen Cross Linking Corneal Pseudomonas Abscess managed successfully with Therapeutic Penetrating Keratoplasty : A Case Report

Ratnali Gandhi<sup>1</sup>, Abhishek Chandra<sup>2</sup>, Sonali Singh<sup>2</sup>, Neha Shilpy<sup>2</sup>, Govind Khalkho<sup>2</sup>

<sup>1</sup>JR 1, <sup>2</sup>Consultant,  
Netrodaya The Eye City, Varanasi

## Abstract

Corneal collagen cross linking with riboflavin (C3R) is a well-established procedure for halting the progression of keratoconus. We report the case of a 35-year-old male who developed pseudomonas associated corneal abscess following C3R for keratoconus after 4 days and was managed with therapeutic penetrating keratoplasty (TPK) and topical antibiotics sensitive to pseudomonas.<sup>1</sup> This case highlights the importance of early recognition and timely surgical intervention in post-C3R infectious keratitis.

**Key words :** Pseudomonas , Collagen, Cross linking, Keratoplasty .

## Introduction

Keratoconus is a progressive ectatic corneal disorder that compromises vision quality. Corneal collagen crosslinking with riboflavin (C3R) has emerged as the gold standard in halting keratoconus progression.<sup>ii</sup> Despite its high safety profile, rare complications such as infectious keratitis have been documented.<sup>iii</sup> Among the causative pathogens, Staphylococcus aureus and other gram-positive bacteria are most common, while Pseudomonas aeruginosa is an uncommon but highly aggressive organism associated with poor prognosis. Here, we present a rare case of post-C3R pseudomonas keratitis that required therapeutic penetrating keratoplasty.

## Case Report

A 35-year-old male from Gorakhpur, Uttar Pradesh, employed in Saudi Arabia presented with pain, redness, discharge, and rapid diminution of vision in the right eye for 4 days following C3R Surgery in both eyes 7 days back. The patient was referred for us for urgent Therapeutic Keratoplasty.

On examination, his vision was only Perception of light in right eye. On slit lamp examination a corneal ulcer with an epithelial defect of size 8 × 9 mm, with dense stromal infiltrates with surrounding stromal edema, central corneal

thinning and blood tinged surface was seen as shown in Figure1-2.

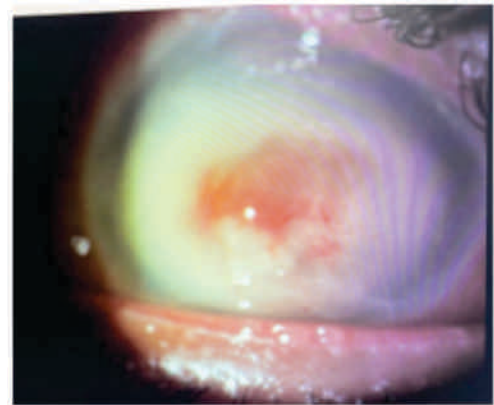


Figure 1 : Stromal abscess with vascularization

Address for correspondence : Ratnali Gandhi  
Netrodaya The Eye City, Varanasi  
E-mail : gandhiratnali21@gmail.com

© UPIOD, 2025 Open Access This article is licensed under a Creative Commons Attribution 4.0 International License, which permits use, sharing, adaptation, distribution and reproduction in any medium or format, as long as you give appropriate credit to the original author(s) and the source, provide a link to the Creative Commons licence, and indicate if changes were made. The images or other third party material in this article are included in the article's Creative Commons licence, unless indicated otherwise in a credit line to the material. If material is not included in the article's Creative Commons licence and your intended use is not permitted by statutory regulation or exceeds the permitted use, you will need to obtain permission directly from the copyright holder. To view a copy of this licence, visit <https://creativecommons.org/licenses/by-nc-sa/4.0/>.

**How to cite this article:** Gandhi R, Chandra A, Singh S, Shilpy N, Khalkho G; Post-Collagen Cross Linking Corneal Pseudomonas Abscess managed successfully with Therapeutic Penetrating Keratoplasty: A Case Report. UP Journal of Ophthalmology. 2025;13(3): 121-123.

**Received:** 03-05-25, **Accepted:** 20-06-25, **Published:** 26-09-25



**UP JOURNAL OF OPHTHALMOLOGY**

An Official Journal of Uttar Pradesh State Ophthalmological Society,  
UPSOS (Northern Ophthalmological Society, NOS)

p-ISSN: 2319-2062

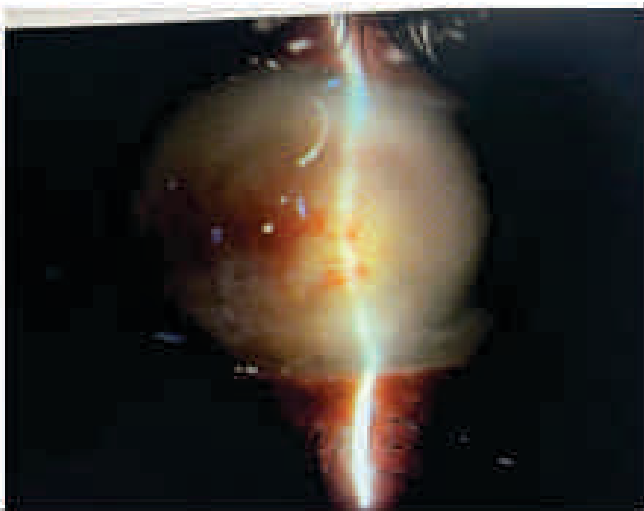

Figure 2 : Slit Photograph of corneal Abscess

Left eye was within normal limits with vision of 6/18. Past history revealed bilateral C3R for keratoconus performed 7 days prior at another hospital. The patient was on topical moxifloxacin eye drops and lubricants postoperatively but the patient had severe pain and photophobia.

A diagnosis of post-C3R Corneal abscess was made and an urgent USG B Scan was advised to see the posterior segment involvement. B- scan did not show any exudates or foci in the posterior segment. (Figure 3)

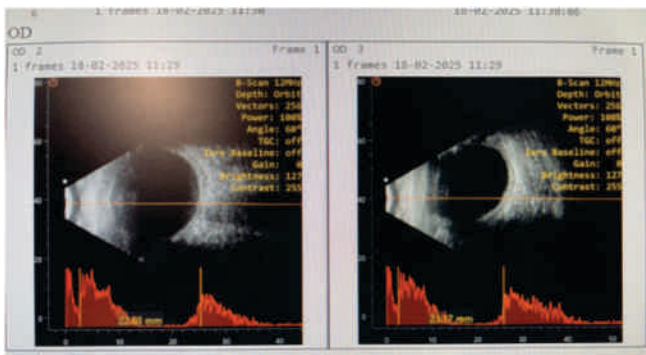


Figure 3 : B-Scan of the patient

Taking into account the rapid progression and corneal thinning, the patient was advised to go urgent therapeutic penetrating keratoplasty (TPK) under guarded visual prognosis. The patient gave his consent and a large diameter therapeutic keratoplasty was done. The excised corneal button was sent for microbiological analysis, which revealed the growth of *Pseudomonas aeruginosa*, sensitive only to meropenem (Figure 4). Fortified Meropenem eye drops were prepared (50 mg/ml) and administered half hourly.

Culture isolated: Organism *Pseudomonas Aeruginosa*.

Sr.No	ORGANISM	SENSITIVE OR RESISTANT
1	Meropenem	Sensitive
2	Piperillin- Tazobactam	Resistant
3	Moxifloxacin	Resistant
4	Levofloxacin	Resistant
5	Tobramycin	Resistant
6	Amikacin	Resistant
7	Ceftazidime	Resistant

Figure 4 : Sensitivity Report

On post-op day 1, vision was counting fingers close to face, corneal edema and desemet's membrane folds were present along with air bubble (Figure 5).

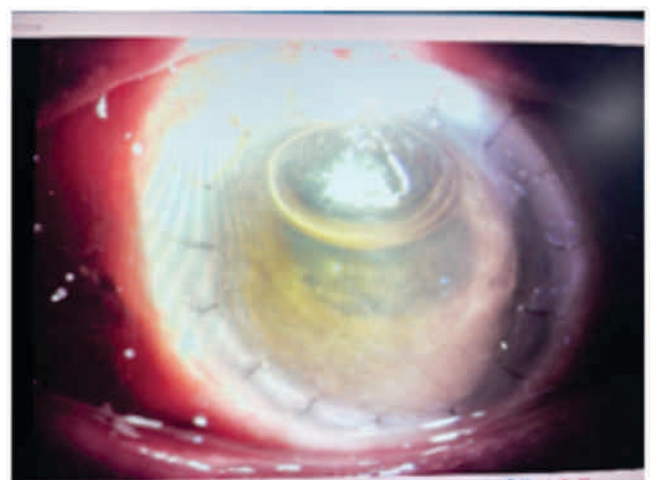


Figure 5 : Post-op Day 1 of TPK

On post op day 5 corneal edema and DM folds were reduced, patient visual acuity of counting finger at 3m vision (Figure 6).

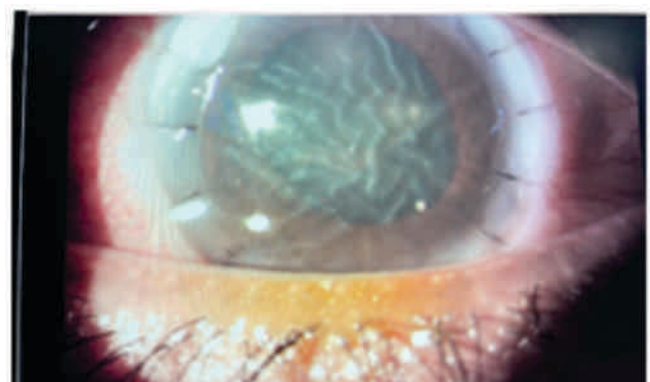


Figure 6 : Post-op Day 5

Patient was followed up on day 14, he had 6/60 vision with mild corneal edema (Figure 7).

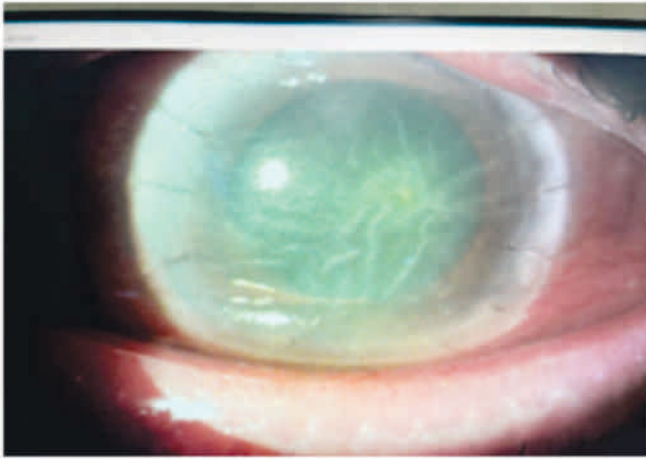


Figure 8 : Post-op Day 14 with corneal edema

and on post op day 30 patient's vision was 6/18, the cornea was clear with intact sutures(Figure 8).

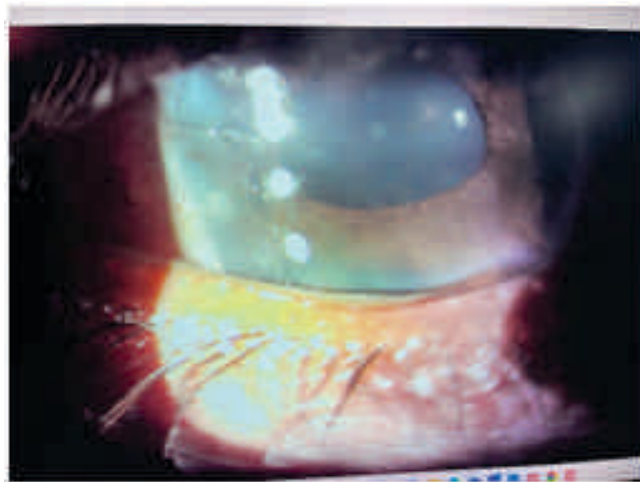


Figure 8 : One month Post-op with Clearer Cornea

It has been now more than 5 months now and the patient is maintaining his vision without any recurrences.

## Discussion

Post-C3R infectious keratitis is a rare but serious complication.<sup>iv</sup> A review of 49 eyes with post-C3R keratitis revealed that bacterial infections (especially *Staphylococcus*

*aureus*) are the most common, while fungal infections were rare. Only two reported cases involved *Pseudomonas aeruginosa* but none of the case was only sensitive to Meropenem.

*Pseudomonas aeruginosa* is notorious for rapid corneal destruction due to its proteolytic enzymes and resistance patterns.<sup>v</sup> In our case, the isolate was resistant to common antibiotics like moxifloxacin, cefazolin and sensitive only to meropenem, necessitating customized fortified eye drop preparation. Early surgical intervention with TPK, coupled with targeted antimicrobial therapy, was crucial for improving vision, resulting in a remarkable recovery to 6/18 within one month.

## Conclusion

Although C3R is a safe and effective procedure for keratoconus, rare postoperative infections can occur, with *Pseudomonas aeruginosa* being particularly aggressive. This case emphasizes the need for vigilance, early microbiological diagnosis, and timely surgical management in preventing irreversible visual loss.

## References

- i Hilliam Y, Kaye S, Winstanley C. *Pseudomonas aeruginosa* and microbial keratitis. *J Med Microbiol.* 2020 Jan;69(1):3-13. doi: 10.1099/jmm.0.001110. PMID: 31750813.
- ii Bhattacharyya A, Sarma P, Das K, Agarwal B, Medhi J, Das Mohapatra SS. Safety and efficacy of riboflavin-assisted collagen cross-linking of cornea in progressive keratoconus patients: A prospective study in North East India. *Indian J Pharmacol.* 2019 May-Jun;51(3):157-167. doi: 10.4103/ijp.IJP\_75\_19. PMID: 31391683; PMCID: PMC6644189.
- iii Kodavoor SK, Sarwate NJ, Ramamurthy D. Microbial keratitis following accelerated corneal collagen cross-linking. *Oman J Ophthalmol.* 2015 May-Aug;8(2):111-3. doi: 10.4103/0974-620X.159259. PMID: 26622139; PMCID: PMC4640035.
- iv Iovieno A, Burgos-Blasco B, Chan D, Ling S, Holland S, Yeung SN. Antibiotic resistance of *Pseudomonas aeruginosa* from ocular samples in Canada: a 25-year analysis. *Ocul Surf.* 2025 Jul 30;38:187-194. doi: 10.1016/j.jtos.2025.07.011. Epub ahead of print. PMID: 40749993.
- v Kato N, Ide T, Kobashi H, Toda I. Infectious keratitis after corneal crosslinking for keratoconus caused by levofloxacin-resistant microorganisms. *BMC Ophthalmol.* 2021 Aug 31;21(1):317. doi: 10.1186/s12886-021-02081-4. PMID: 34465309; PMCID: PMC8409002.