Case Report

Axenfeld-Rieger Syndrome with Glaucomatous Progression Following Treatment Non-adherence : A Case Report

Priyanka Gupta, Prakriti Pokhryal, Rajyeshwar Singh

Department of Ophthalmology, Shri Guru Ram Rai Institute of Medical and Health Sciences, Dehradun, Uttarakhand, INDIA – 248001

Abstract

Background: Axenfeld-Rieger syndrome (ARS) is a rare autosomal dominant disorder caused by mutations in developmental transcription factors FOXC1 or PITX2. A 22-year-old female presented with bilateral ocular pain and headaches following a 6-month hiatus in antiglaucoma therapy. Ocular examination revealed posterior embryotoxon, angle dysgenesis (IOP: 28.0 mmHg OD, 25.0 mmHg OS), and severe refractive errors (-12.50 D OD, -14.50 D OS). Systemic evaluation identified dental microdontia, maxillary hypoplasia, broad nasal bridge and brachydactyly, consistent with ARS diagnostic criteria. Treatment with Brimonidine tartrate 0.2% + Timolol maleate 0.5% eye drop (twice daily, both eyes) initiated, achieving target IOP. The patient counselling done regarding the chronic nature of the disease and the importance of treatment adherence. This case underscores the critical consequences of treatment non-adherence in ARS-associated glaucoma and reinforces the need for counselling and lifelong IOP monitoring. While genetic testing remains valuable for family counseling, careful clinical phenotyping may suffice for diagnosis in resource-limited settings.

Keywords: Axenfeld-Rieger syndrome, glaucoma, treatment adherence, anterior segment dysgenesis, case report

Introduction

Axenfeld-Rieger syndrome (ARS) is a rare autosomal dominant disorder (estimated incidence 1:200,000) caused by mutations in developmental transcription factors FOXC1 or PITX2.[1] Classically defined as anterior segment dysgenesis including posterior embryotoxon, iris hypoplasia, and corectopia with approximately 50% of patients developing glaucoma by adolescence.[2] While ocular manifestations dominate clinical recognition, ARS is a multisystem disorder, with documented craniofacial, dental, cardiac, and neuroimaging anomalies.[3,4] Diagnostic challenges persist due to phenotypic variability and overlap with other anterior segment dysplasias, such as Peters anomaly.[2] Recent studies highlight underrecognized systemic associations: neuroimaging findings (e.g., cerebellar hypoplasia, vertebrobasilardolichoectasia) and posterior segment abnormalities (e.g., persistent fetal vasculature, foveal hypoplasia).[3,5] Notably, retinal imaging in FOXC1-related ARS reveals subtle structural disruptions even in patients without overt visual complaints,[5] suggesting posterior segment involvement may be more prevalent than previously acknowledged.

Case Presentation

Informed consent obtained from the patient for publication of this case report. A 22-year-old female presented to the Shri MahantIndiresh Hospital Ophthalmology OPD with a one-month history of persistent mild headache and bilateral ocular pain. The onset was sudden, and the symptoms had progressively worsened. Headaches episodes were not associated with any triggering events. she recalled similar

Address for correspondence : Priyanka Gupta
Shri Guru Ram Rai Institute of Medical and Health Sciences, Dehradun, Uttarakhand, INDIA – 248001
E-mail : priyankagupta8405@gmail.com

© UPJO, 2025 Open Access This article is licensed under a Creative Commons Attribution 4.0 International License, which permits use, sharing, adaptation, distribution and reproduction in any medium or format, as long as you give appropriate credit to the original author(s) and the source, provide a link to the Creative Commons licence, and indicate if changes were made. The images or other third party material in this article are included in the article's Creative Commons licence, unless indicated otherwise in a credit line to the material. If material is not included in the article's Creative Commons licence and your intended use is not permitted by statutory regulation or exceeds the permitted use, you will need to obtain permission directly from the copyright holder. To view a copy of this licence, visit https://creativecommons.org/licenses/by-nc-sa/4.0/.

How to cite this article: Gupta P, Pokhryal P, Singh R; Axenfeld-Rieger Syndrome with Glaucomatous Progression Following Treatment Non-adherence : A Case Report. UP Journal of Ophthalmology. 2025;13(3): 124-126.
Received: 04-06-25, **Accepted:** 18-07-25, **Published:** 25-10-25

p-ISSN: 2250-1916

episodes of headaches in the past, which subsided with medications from a local practioner. Notably, she had been using anti-glaucoma therapy instilling Brimonidine tartrate 0.1% composition in the left eye twice daily since 2021 but discontinued this regimen six months before her current presentation. Patient had never used refractive correction.

Systemic Clinical Findings

The patient exhibited distinct craniofacial anomalies, including broad nasal bridge and maxillary hypoplasia (Figure1), dental microdontia (Figure 2) and bachydactyly (Figure 3). No renal, cardiac, or neurological abnormalities were detected on systemic clinical evaluation.



Figure 1 : Broad nasal bridge



Figure 2 : Dental microdontia



Figure 3 : Brachydactyly both hands

Ocular Examination

Uncorrected visual acuity (UCVA) was 6/60 OU. Best-corrected visual acuity (BCVA) in right eye was 6/18 with refractive correction of −12.50 DS /−2.00 DC at 90° ; left eye 6/18 with refractive correction of -14.50 DS / -3.50 DC at 80 degree. Intraocular pressure (IOP) by GAT at 10 AM were 28.0 mmHg OD and 25.0 mmHg OS on presentation .Central corneal thickness (CCT) were 539 µm OD and 528 µm OS. Anterior segment (OU) showed posterior embryotoxon (Fig 4 & 5). Gonioscopy (OU) shows angle dysgenesis. Fundus examination (OU) shows thinning of the inferior neuroretinal rim, vertical cup-to-disc (VCD) ratio of 0.7:1. Previous disc finding & baseline IOP couldn't be documented as patient has lost her all old records.

Based on the clinical presentation marked by anterior segment dysgenesis (posterior embryotoxon, and gonioscopically angle dysgenesis) in conjunction with characteristic facial dysmorphism and brachydactyly a diagnosis of Axenfeld-Rieger syndrome was established.



Figure 4 :
Right eye embryotoxon

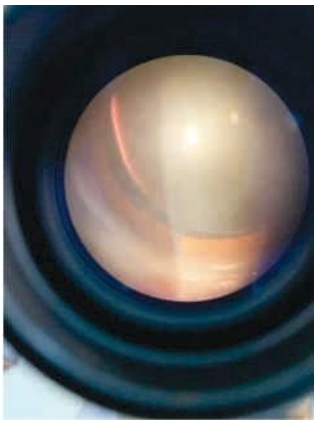

Figure 5 :
Left eye embryotoxon

Therapeutic Intervention

Given the history of discontinued anti-glaucoma therapyand the elevated intraocular pressures on presentation, the patient was promptly advised to resume ocular treatment. The therapeutic regimen prescribed included:

1. Brimonidine Tartrate + Timolol maleate Eye Drops: Twice daily in both eyes (along with punctal occlusion)
2. Sodium hyaluronate 0.1% Eye Drops: Three times daily in both eyes

She was given spectacle correction as per her acceptance. Baseline OCT and perimetry done. The patient was counselled extensively regarding the chronicity of the disease and the potential risk of progressive glaucomatous damage and importance of keeping proper records was emphasized. She was referred to physician for systemic evaluation. At 1 month follow up her IOP were 14mmhg OD & 13mmhg OS. A follow-up was scheduled at six-month intervals to re-evaluate IOP, anterior segment configuration, and optic nerve status.

Discussion

This case exemplifies the clinical and diagnostic complexities of Axenfeld-Rieger syndrome, characterized by the hallmark triad of posterior embryotoxon, angle dysgenesis, and systemic anomalies (dental microdontia, craniofacial dysmorphism, bachydactyly).[1,2] The patient's elevated intraocular pressure (IOP) of OD -28.0 mmHg & OS – 25mmhg following a 6-month hiatus in antiglaucoma therapy underscores the critical role of treatment adherence in mitigating glaucomatous progression, a finding consistent with studies emphasizing IOP volatility in non-compliant ARS patients.[3] This emphasizes the need for structured patient counseling[3] and records keeping is crucial for monitoring disease progression.

Anterior Segment and Glaucoma

The bilateral angle dysgenesis and posterior embryotoxon observed in this case align with the spectrum of anterior

segment dysgenesis described in ARS.[1] Notably, the severity of refractive error (-14.50 D in the left eye) exceeds typical ARS presentations, suggesting phenotypic variability even among patients without confirmed FOXC1/PITX2 mutations.[4] While genetic testing was unavailable in this case, prior work highlights the association of FOXC1 variants with severe anterior chamber anomalies[4], reinforcing the need for molecular diagnostics in resource-available settings.

Systemic Manifestations

The patient's dental microdontia and craniofacial features (broad nasal bridge, maxillary hypoplasia & bachydactyly) mirror systemic findings reported in multi system ARS case studies [2,5]. Notably, the absence of cardiac or neuroimaging abnormalities contrasts with reports of verte brobasilardolichoectasia and cerebellar hypoplasia in ARS[5], highlighting the condition's heterogeneous expressivity.

Posterior Segment Findings

Contrary to studies documenting congenital optic nerve dysplasia or persistent fetal vasculature in ARS[6], this patient's fundus evaluation revealed only glaucomatous optic neuropathy. This divergence may reflect genotypic differences or underrecognized phenotypic subgroups, warranting further investigation with advanced retinal imaging.

The absence of posterior segment anomalies in this patient contrasts with studies documenting congenital optic nerve dysplasia in FOXC1-positive ARS[4], emphasizing the phenotypic heterogeneity of the disorder. While genetic testing was unavailable, clinical findings (craniofacial dysmorphism, severe refractive errors) suffice for diagnosis in resource-limited settings .[1]

Dental microdontia and craniofacial dysmorphism necessitate collaboration with dentists and geneticists, as advocated by recent ARS management guidelines. [5]

The patient expressed significant relief after resuming treatment and noted that she had not understood the chronic nature of her condition, believing the medication was only needed temporarily. She committed to maintaining regular follow-up appointments after understanding the progressive nature of glaucoma associated with her syndrome.

Conclusion

Multidisciplinary care remains paramount, as dental microdontia, bachydactyly and craniofacial anomalies necessitate collaboration with dentists and geneticists. Future studies should prioritize genotype-phenotype correlations, particularly in patients with severe refractive errors or atypical posterior segment findings.[6]

References

1. Li K, Tang M, Xu M, Yu Y. A novel missense mutation of FOXC1 in an Axenfeld–Rieger syndrome patient with a congenital atrial septal defect and sublingual cyst: a case report and literature review. BMC Med Genomics. 2021;14(1):267.
2. PremSenthil M, Knight LSW, Taranath D, Mackey DA, Ruddle JB, Chiang MY, et al. Comparison of anterior segment abnormalities in individuals with FOXC1 and PITX2 variants. Cornea. 2022 Aug;41(8):1009-15.
3. White S, Taranath A, Hanagandi P, Taranath DA, To MS, Souzeau E, et al. Neuroimaging findings in Axenfeld-Rieger syndrome: a case series. AJNR Am J Neuroradiol. 2023;44(10):1231-5.
4. Gołaszewska K, Dub N, Saeed E, Mariak Z, Konopińska J. Axenfeld-Rieger syndrome combined with a foveal anomaly in a three-generation family: a case report. BMC Ophthalmol. 2021;21(1):158.
5. Jacobson A, Bohnsack BL. Posterior segment findings in Axenfeld-Rieger syndrome. J AAPOS. 2022;26(6):320-2.
6. Untaroiu A, Reis LM, Higgins BP, Walesa A, Zacharias S, Nikezic D, et al. In vivo assessment of retinal phenotypes in Axenfeld-Rieger syndrome. Invest Ophthalmol Vis Sci. 2024;65(4):20.